THE VALUE OF RADIOGRAPHY IN THE DIAGNOSIS AND TREATMENT OF URINARY STONE

THE VALUE OF

RADIOGRAPHY IN THE DIAGNOSIS AND TREATMENT OF URINARY STONE

A STUDY IN CLINICAL AND OPERATIVE SURGERY

BY

E. HURRY FENWICK, F.R.C.S.

SURGEON TO, AND A LECTURER ON CLINICAL SURGERY AT THE LONDON HOSPITAL; FELLOW OF THE ROYAL SOCIETY OF MEDICINE; MEMBER OF THE INTERNATIONAL SURGICAL SOCIETY, ASSOCIATION INTERNATIONALE D'UROLOGIE; CORRESPONDING MEMBER ASSOCIATION FRANCAISE D'UROLOGIE, AMERICAN ASSOCIATION OF GENITO-URINARY SURGEONS, AMERICAN UROLOGICAL ASSOCIATION, DEUTSCHEN GESELLSCHAFT FÜR UROLOGIE

LONDON
J. & A. CHURCHILL
7, GREAT MARLBOROUGH STREET
1908

BY THE SAME AUTHOR.

DIE VENEN DER VORDEREN RUMPFWAND DES MENSCHEN. With Prof. W. BRAUNE. (Veit & Co., Leipzig.) 1884.

THE ELECTRIC ILLUMINATION OF THE BLADDER AND URETHRA. Second Edition. (Churchill.) 1889.

THE CARDINAL SYMPTOMS OF URINARY DISEASE. (Churchill.) 1893.

ATLAS OF ELECTRIC CYSTOSCOPY. With Dr. E. BURCKHARDT, of Basel. (Churchill.) 1893.

CHIRURGIE DER NIEREN: KLINISCHES HANDBUCH DER HARNORGANE. (Vogel, Leipzig.) 1899.

DISEASES OF THE URINE. Twentieth Century Practice of Medicine. (Wood & Co.) 1895.

MODERN URINARY SURGERY. An Epitome of the Literature. Second Edition. (Wright & Co.) 1895.

TUMOURS OF THE URINARY BLADDER. Jacksonian Prize Essay. Fasc. i. (Churchill.) 1897.

SURGICAL AFFECTIONS OF THE KIDNEY. Encyclopædia Medica, vol. vi. (William Green and Co.) 1900.

ULCERATION OF THE BLADDER. Simple, Tuberculous, and Malignant. (Churchill.) 1900.

OPERATIVE AND INOPERATIVE TUMOURS OF THE BLADDER. A Clinical and Operative Study based on Five Hundred Cases. (Churchill.) 1901.

OBSCURE DISEASES OF THE URETHRA IN BOTH SEXES. (Churchill.) 1902.

URETERIC MEATOSCOPY IN OBSCURE DISEASES OF THE KIDNEY. (Churchill.) 1903.

THE ENLARGED PROSTATE: What is the best form of Operative Treatment for its Cure? (Churchill.) 1903.

HANDBOOK OF CLINICAL CYSTOSCOPY. (Churchill.) 1904.

GOLDEN RULES OF SURGICAL PRACTICE. Seventh Edition. (Wright & Co.)

TO THE

DEUTSCHEN GESELLSCHAFT FÜR UROLOGIE

IN ITS

FIRST CONGRESS AT VIENNA

1907

PREFACE

TWO groups of professional workers are mainly concerned in a careful study of shadows cast by the Röntgen rays in the urinary tract—the operator and the radiographer. Both work independently and yet both are interdependent. The former cannot justly cast the responsibility of shadow deduction upon the latter, though he is dependent upon him for skill in shadow detection. The radiographer cannot be content with merely producing shadows: he must aspire to the knowledge of their causation, and to obtain this he must examine critically and learn from the work of the operator. Each must give: each take.

Some such line of thought as this has prompted me to repay some small part of my own indebtedness to radiography by attempting to assist beginners in the study of the correct estimation of shadows. I have therefore collected my oral teaching upon the X-ray negatives which are brought with each patient to my operating theatre at the London Hospital. The negatives[1]—for I distrust the prints—are examined, compared with the clinical history, and explained, as far as is possible, immediately before the operation is carried out. The onlooker is thus able to gauge the accuracy or failure of the negative. As I have mainly used hospital negatives for my teaching I have only reproduced those recently[2]

[1] Over 1000 in number.

[2] Compare footnote on pages 51, 52.

supplied by our radiographic department, with the exception of one or two striking illustrations from negatives from my private practice, which were taken for me by such well-known experts as Mr. Mackenzie Davidson, Mr. Reid, Mr. Lyster, and Mr. Thurstan Holland. *I need hardly say no plate has been "improved upon" or "touched up,"* except Plate XX. The general accuracy and clearness of the negatives are due to the unremitting care and skill of Mr. Harnack and Mr. Wilson, of the Radiographic Department of the London Hospital, and I seize this opportunity of expressing my indebtedness and my gratitude to them for all the trouble and attention they have shown.

My especial thanks are due to our registrar, Mr. F. S. Kidd, for his careful examination of thirty bodies I had had radiographed for the study of phlebolith shadows. I have inserted his valuable and convincing remarks upon the observations he made, and I have supplemented his work with notes of my own dissections of the venous systems of the pelves of fifty bodies. Others have talked vaguely of having seen phleboliths and phlebolith shadows, but up to the present no careful or systematic work has been done upon the subject.

The rules I give are crude and tentative only. They will doubtless receive that criticism and correction which increasing experience alone can exercise. Their weakness should be condoned by the fact that the method is still in its infancy.

E. HURRY FENWICK.

14, SAVILE ROW.

CONTENTS

LIST OF PLATES

SUGGESTED RULES

PLATE I.

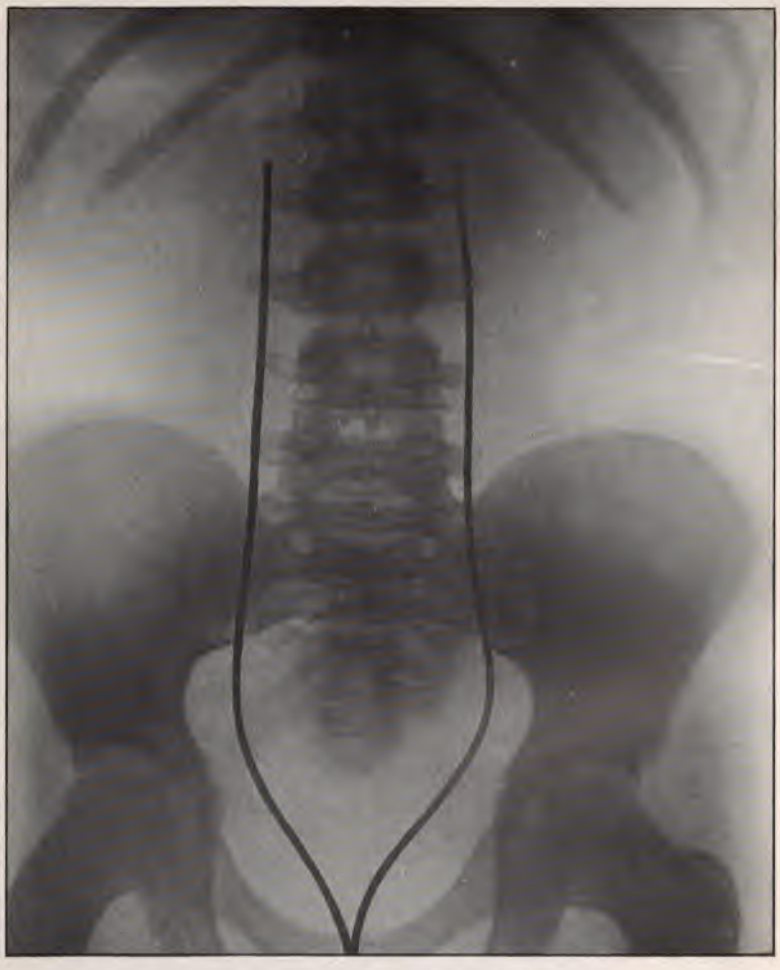

Radio-diagram of the male urinary tract showing the line of the ureters.—(E. H. H.)

Engraved and printed by Bale & Danielsson, Ltd.

CHAPTER I.

It has been my custom for twenty years to write down clearly my diagnosis of every obscure case in urinary surgery and often to make a rough pen and ink sketch of the presumed disease before proceeding to operate. The facts of the operation have then been added in detail to the history and the condition actually discovered has been compared with that which was anticipated. The result has, of course, been often most humiliating, but I know of no habit more valuable in building up accurate clinical knowledge than this; certainly nothing can be more salutary for an operator or more instructive for a student.

To save time I employ diagrams of various kinds, and in radiography, where one observer has to point out shadows which he may detect and another overlook, or to which he may attach importance and another ridicule, a diagram is not only invaluable but all essential.

PLATE I.

Diagram used in the Author's Wards at the London Hospital.

This radiogram was taken from a boy, aged 7, in order to get a clear and comprehensive diagram of the relations of the various sections of the urinary tract to the adjacent osseous structures. The two long vertical

lines represent the course of the ureters in the male. The accuracy of their position will be evident if this diagram is compared with the radiograms of the trunks of male adults on whom the ureteric shadowgraph bougie had been passed prior to the X-ray photographs being taken. Compare Plates XLV, XLVII, XLVIII, LVIII.

PLATE II.

Bismuth-covered scybala in the bowel of a little girl causing shadows like "stone-shadows" in right kidney area and bladder. Arrowed.—(J. MACKENZIE DAVIDSON.)

Engraved and printed by Bale & Danielsson, Ltd.

PLATE II.

SHADOWS, WHITE-ARROWED, CAST BY BISMUTH-COVERED SCYBALA.

This plate is introduced to illustrate the first rule in radiography :

Rule 1.—Clear out the bowels with a vegetable purge before submitting the patient to radiography.

A casual glance at this radiogram will convey the impression that there are four stones in the bladder and three other suspicious shadows in the right renal area, any or all of which might indicate calculi in these organs.

These shadows were cast, however, by bismuth-covered scybala in the rectum and in the large intestine. A free purge removed them, and the radiogram taken immediately after the free evacuation of the bowels was perfectly clear and normal.

Clinical history.—A little girl, aged 7, was brought to me by Mr. Blucke, of Shaftesbury, with a diagnosis of right-sided hydronephrosis, which was becoming infected from the bowel (coli-pyelitis). In consultation this diagnosis was accepted and the child was radiographed by Mr. Mackenzie Davidson, who drew my attention to some stone-like shadows in the bladder and right kidney (Plate II). Inquiry was immediately made as to what medicine the little girl had been taking, and it was found that the nurse had given her a saline phosphate and bismuth mixture. A purgative removed a quantity of scybala powdered with phosphate and bismuth.

On operation the right renal pelvis was found much dilated. This was supposed to be due to a kink in the ureter, but a year subsequently the girl developed acute

perforative peritonitis. She was operated upon, but died in a few hours. On post-mortem the right ureter was found adherent to the appendix and almost occluded.

The reader is advised to compare this plate of intestinal shadows with the next (Plate III). The similarity will impress upon him the paramount importance of the rule.

PLATE III.

Shadows of four stones in the bladder of a boy aged 4. Litholapaxy: cured.—(E. H. H.)

Engraved and printed by Bale & Danielsson, Ltd.

PLATE III.

SHADOWS OF FOUR STONES (WHITE-ARROWED AND NUMBERED) IN THE BLADDER OF A BOY, AGED 4.

These true shadows, cast by stones in the bladder, compare strikingly with the false shadows (marked with the same figures in the preceding plate) produced by bismuth-covered scybala in the rectum.

Clinical history.—The stones were crushed with a 6 E lithotrite, and evacuated by means of a 10 E cannula.

The stones were composed of oxalates covered with phosphatic material, each being the size of a monkey nut.

The boy was playing about the ward four days after the operation.

CHAPTER II.

REMARKS UPON THE CHARACTER OF THE SHADOWS CAST BY STONES.

To avoid needless repetition it is well to enumerate several points regarding the character of the radiographic shadows cast by stones in the urinary tract.

A just appreciation of the "character" of a shadow depends on the following points: (1) its density, (2) its shape and size, (3) its position.

It will be noticed that nothing is said about a clue to the actual number of stones which each shadow represents. The novice, in his enthusiastic desire for scientific accuracy and dogmatic statement, may be inclined to consider each shadow represents one stone, and therefore to state that such and such a number of stones are present and must be removed, because so many shadows can be counted. A little experience in the fusion of shadows will convince him that it is wiser to state a shadow represents a "*stone patch,*" for it may point to a "clutch" of stones rather than a single stone. Thus in Plate IV two large shadows in the right kidney area (transverse arrows) were proved to be cast by 400 cystine stones, whilst the irregular shadow in the left kidney area (vertical arrows) was cast by 10 stones.

PLATE IV.

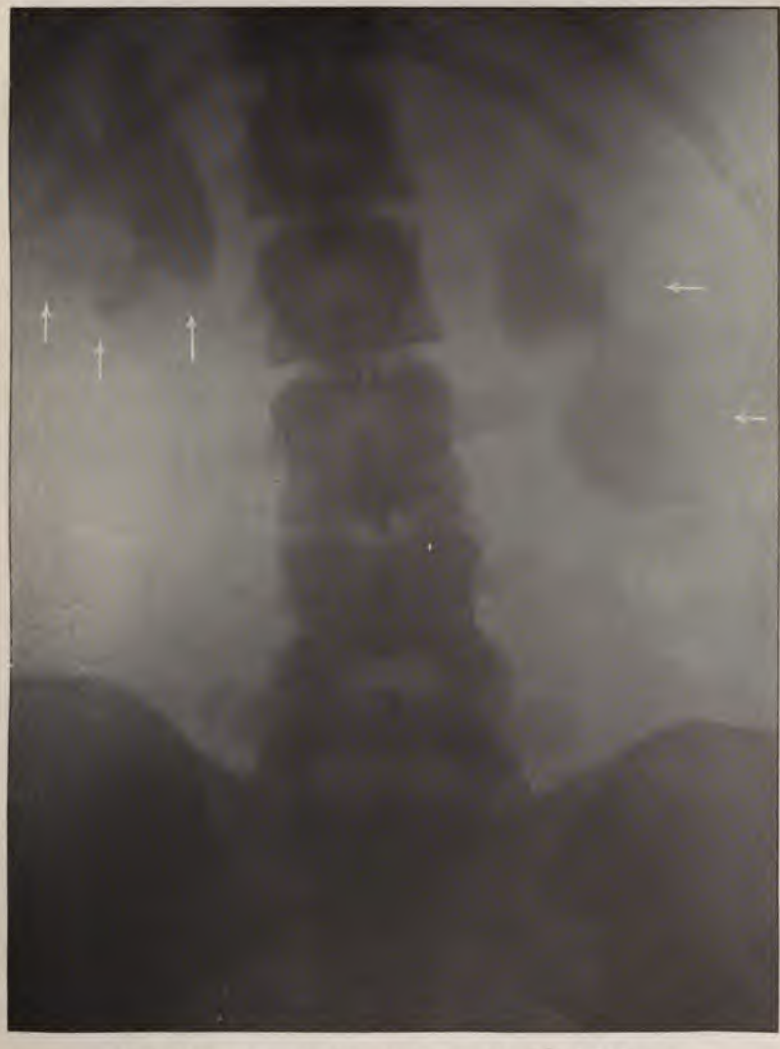

Multiple cystine calculi (white-arrowed) in both kidneys.
(Taken by Mr. Lyster.)

PLATE V.

A single shadow (black-arrowed) of a clutch of seven stones in the left kidney pelvis of Mis D—.

PLATE V.

A Single Shadow (Black-arrowed) of a Clutch of Stones in the Left Kidney Pelvis of a Young Woman.

Another good illustration of the fusion of individual shadows is represented in Plate V. The radiograph was taken by Mr. Harnack of a young woman, Miss D—,

Fig. 1.—Clutch of seven stones, natural size, from Miss D—.

aged 22, sent to me by Dr. Gabb, of Guildford. On touching the pelvis of the left kidney with the finger it was felt to be occupied by a clutch of stones. They were removed (Fig. 1) and found to be seven in number. Six were composed of lime phosphate and one, the smallest and lowest, of oxalate of lime.

The fusion of many small shadows into one takes place

most easily and most often, I believe, in cortical collections—that is, when small stones are closely packed in a *dry* dilated calyx.

Rule 2.—A sharply defined, small, single shadow in the renal area usually denotes one stone is present, but many small stones may be represented by one shadow.

PLATE VI.

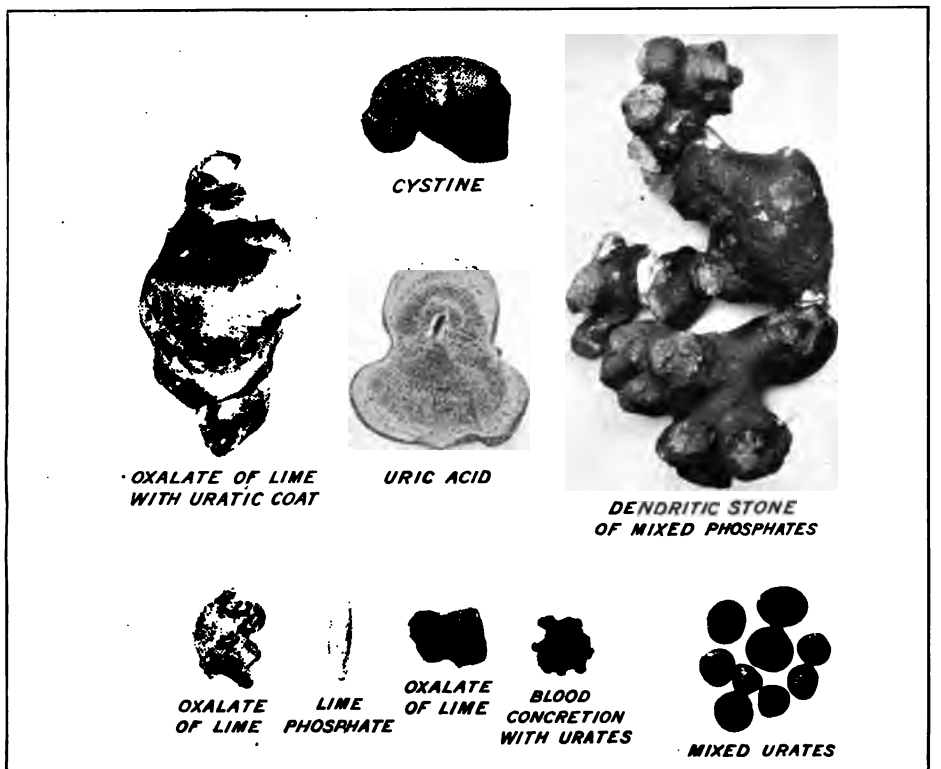

PHOTOGRAPH OF STONES.

Clinical Inferences which may be Drawn from the Density of the Shadow.

(1) *The density.*—If extremely dense shadows are noticed it may be inferred that the stones are composed mainly of oxalate of lime, for these, of all the stones, resist most effectually the penetration of the X ray.

Cystine stones approach the oxalate of lime stones in density (compare Plate IV, which illustrates cystine calculi in the kidney); but these calculi are so rarely met with that they may be regarded as a negligible quantity.

Phosphate of lime stones of the aseptic type rank next, often casting lighter shadows than the preceding, though, of course, the larger the stone the deeper the shadow; whilst stones composed of "mixed" phosphates (ammonio-magnesic phosphate or triple phosphates) are very difficult to detect, because the rays easily permeate these varieties. The pure uratic stones are rarely recognised in an X ray, for the rays pass through them without much hindrance. The only rule one can gather from this has to be combined with clinical experience. It is as follows:

Rule 3.—A sharply-defined dense shadow in the renal area of a young adult who suffers from symptoms of stone (the urine being oxalescent and aseptic) indicates an oxalate of lime calculus.

I place before the reader a series of kidney stones first photographed (Plate VI) and then radiographed upon a plate (Plate VII), so as to show their visual character with their X-ray densities. I do this because it is customary to give such a plate. But I warn the reader that it is of but little practical value, for the tissues of the body, and, above all, the structure of the kidney, entirely change the character of the density of most stones.

At present our knowledge of how an inflamed or how a congested kidney acts in transmitting or impeding the X ray is small and inaccurate. I refer the reader to the end of the book (page 126) where I allude to this subject again.

Clinical Inferences which may be Drawn from the Shape of the Shadow.

(2) *Shape.*—The shape of the shadow, if well defined, often gives the surgeon a fair idea of the shape and size of the stone or stones he has to deal with. This is especially the case if the stone be of the oxalate or cystin groups; but it is otherwise with those stones which are mainly composed of phosphates. Here the shadow is densest where the stone is thickest, and the edges and rays, or connecting bars between the thick bosses throw but a very faint shadow. It is especially difficult to estimate the shape and size of a *dendritic* stone, this being always composed of phosphatic casts of the renal pelvis and calices. Some of the rays or branches may be almost translucent. No exact impression is thus conveyed to the operator by the X ray as to how many or which calices are occupied by the club ends of the rays; he merely knows that he has to deal with a dendritic stone and has to be extra careful in discovering and removing all the terminal cusps.

Clinical Inferences which may be Drawn from the Position of Stone Shadows.

(3) *Position.*—The operator and clinician may often gather reliable and even valuable information by noting the exact position which the stone shadow assumes in the radiograph.

Three items of knowledge are, however, necessary, and indeed indispensable, before any sound conclusion can be drawn from the mere *position* of the shadow.

(*a*) Where was the tube placed in taking the radiograph; was it placed mesially [1] or to either side?

[1] In most of the radiographs I have had taken for me, over 1000 in number, the light has been placed mesially, either at or above the umbilicus for the kidney or below it for the viscera of the bony pelvis.

PLATE VII.

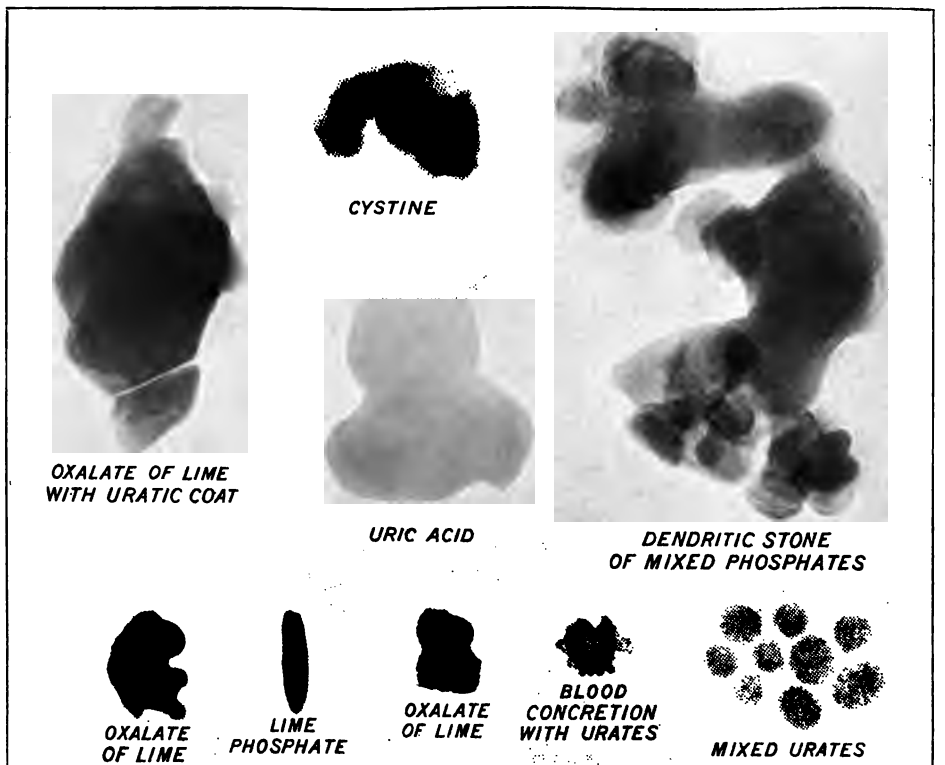

RADIOGRAPH OF SAME STONES.

Shadows cast by the rays are obviously distorted and displaced according to the position of the tube. A clever radiographer will often utilise this fact by throwing his light obliquely, whenever he sees the shadow of a rib or transverse process darker at one spot than normal. This exaggeration of shadow points to a stone shadow coalescing with the shadow of the bone, and by throwing the light obliquely he can often detach, so to speak, the stone shadow from that cast by the bone (compare page 28).

(*b*) Is the kidney in which the stone is lodged mobile or displaced? The shadow of a stone in a mobile kidney will obviously move, and, therefore, be less easily defined by the light, whilst a stone in a displaced kidney may be far out of the position usually assigned to it. Mobility or displacement can be easily ascertained by the usual bimanual examination if the patient is moderately thin, but no surgeon of any experience would care to speak definitely either of mobility or displacement of the kidney in an obese subject; a marked mobility or displacement must always weigh with the clinician in interpreting a radiograph of the kidney.

(*c*) Was the tube in front and the plate behind the body, *or vice versâ*[1]—in other words, which is the right and which the left side of the negative?

[1] It might be thought that this is a childish or a fussy question; I know for a fact one patient was operated on and the wrong kidney explored for the want of a simple expedient such as a metal L to mark the left side of the patient.

PLATE VIII.

To Locate a Shadow.

Landmarks for Dividing the "Loin Space," in order to Fix the Position of the Shadow.

To obtain a ready grasp of the position of the shadows and in order to collect accurate data for clinical inferences, it is necessary to possess landmarks.

The "loin space" which appears, or should appear in every radiograph of a urinary case, is that space which lies between the shadows cast by outer edge of spine, the iliac crest and the lowest rib. It should be bisected by an imaginary line running vertically from the centre of the iliac crest shadow to the rib (Plate VIII). In my own teaching I call this the mid-ileo-costal vertical line, or, briefly, the "mid-vertical." It divides the loin space into an inner and an outer division. Much, in my opinion, depends upon this bisecting line in the due appreciation of the nature of shadows.

PLATE VIII.

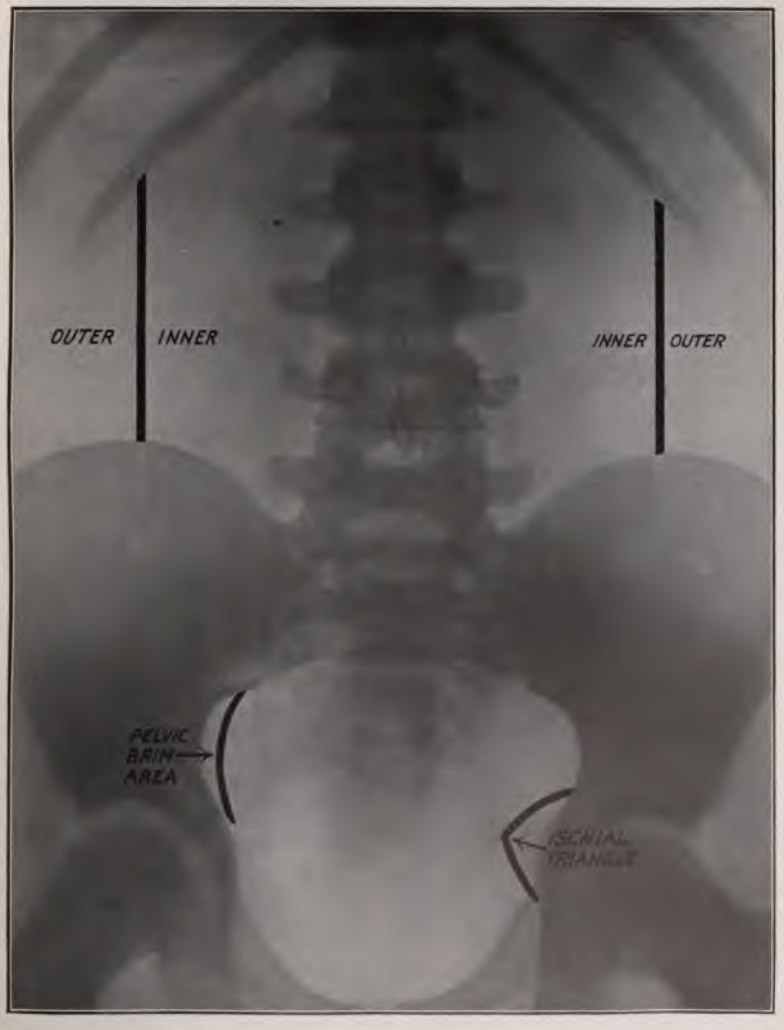

The vertical bisection of the loin space by a mid-vertical.

PLATE IX.

A metal monkey in the descending colon (arrowed) of a child, to show how easily foreign bodies in the bowel can throw shadows on to the renal areas.—(E. H. H.)

Engraved by Bale & Danielsson, Ltd.

Significance of the Mid-Vertical.

The mid-vertical is of great assistance to me in rapidly interpreting the significance of shadows which appear in the loin spaces.

(1) It will be found that shadows outside the mid-vertical are usually cast by contents in the bowel.

(2) Shadows inside the mid-vertical are usually urinary shadows or rarely cretaceous gland shadows; occasionally they may be bowel.

(3) Shadows arranged along the mid-vertical or near it are not infrequently collections of stone in the **cortical** portion of the kidney.

Each of these statements should be considered in detail.

(1) *Shadows outside the mid-vertical.* — Without any dogmatic statement being made I would ask the reader to look at Plate IX. If he slightly turns the radiogram to the left he will notice a shadow in the shape of a monkey in the left loin space, outside the mid-vertical.

Mr. Harnack took this radiogram from a child who had swallowed a metal monkey; it is obviously in the large bowel.

Rule 4.—Any shadow outside the mid-vertical should immediately arrest attention, for it demands explanation. The surgeon should hesitate to diagnose such a shadow as urinary without further investigation.

This rule does not assert or convey the idea that bowel shadows are not seen *within* the mid-vertical, far from it; they are *often* witnessed there. Look for a minute at Plate II of a little girl who had been taking a phosphate aperient. I challenge anyone not knowing the clinical aspects of the case as I did, to recognise such shadows as phosphatic-covered fæces, and not to mistake them for renal calculi. The rule only advises a cautious diagnosis in shadows outside the mid-vertical.

The reader will do well to glance at page 104, where an appendix concretion is figured.

(2) *Shadows inside the mid-vertical.*—Most stones in the kidney are lodged in the pelvis of the organ. As this faces, anatomically, the vertebral column, shadows cast by renal pelvic stones are generally near that osseous structure, and hence well to the inner side of the mid-vertical. Some kidneys are displaced, even in men, and the shadow of the pelvic stone is therefore also displaced from this, the usual position, but even then the shadow nearly always lies within the mid-vertical or on that line. Plate X is the radiograph of a gentleman aged 50, a patient of Dr. Barnes, of Streatham, with a very loose and displaced kidney. The shadow in this instance lies in the mid-vertical, blending and almost hidden by the tip of a long last rib. It was removed.

Rule 5.—Even making allowance for abnormal position, and even for extreme downward displacement of the kidney, the shadows of stones in the kidney will still fall (if the lamp be mesial) within or on the mid-vertical.

Other illustrations of the varying positions of pelvic stone may be given; in each the shadow falls in such a way as to agree with the rule, no matter how greatly the kidney is displaced downwards.

PLATE X.

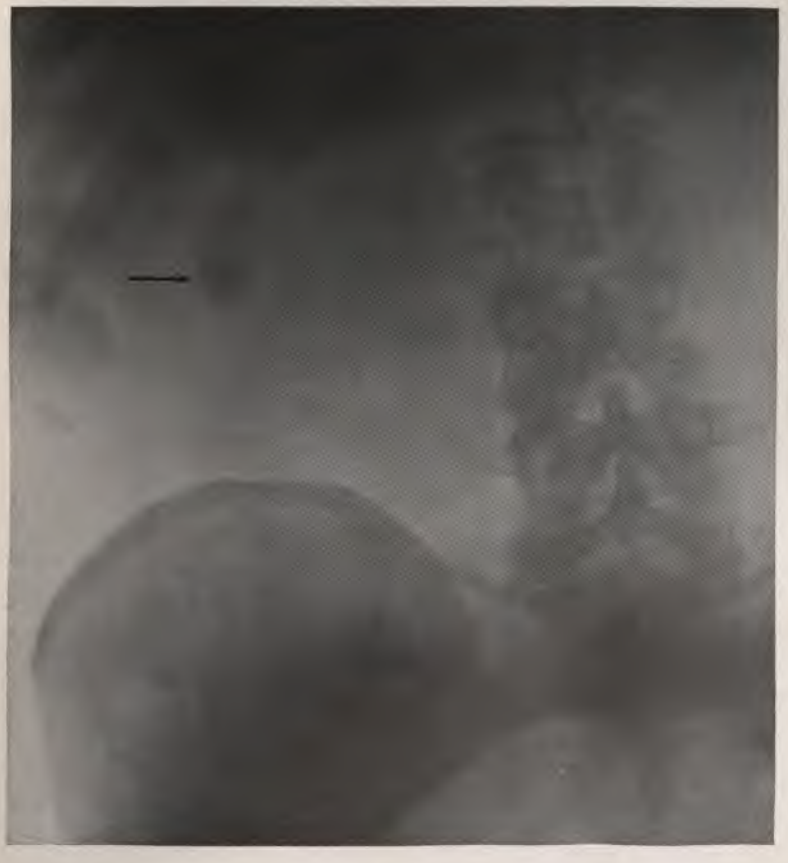

Shadow of an oxalate of lime stone (black-arrowed) in the left pelvis of a displaced loose kidney of a man.

PLATE XI.

An oxalate ureteric "plug-stone" which had destroyed left kidney without producing any symptoms except a pyuria.—(E. H. H.)

Engraved and printed by Bale & Danielsson, Ltd.

Plate XI.

Illustration 2.—Shadow of a stone plugging the ureteric orifice of the pelvis in a *displaced* kidney seen inside the mid-vertical.

This plate shows an oval shadow midway between the rib and the ilium and inside the mid-vertical. It was cast by an oxalate of lime stone which had plugged the pelvic orifice of the left ureter and had thus completely destroyed the left kidney by back pressure, but without producing any symptoms of pain.

Clinical history.—Miss B— was sent me by Dr. Shettle, of Southampton, with pyuria, emaciation, and a "tired" sacral pain. On examination with the cystoscope, pus was seen issuing from the left ureteric orifice, and the patient was then X-rayed (Plate XI).

Operation.—The kidney was approached by the left lumbar incision and found to be a mere collection of cysts fixed to its surroundings by dense adhesions. An oxalate of lime stone was found in the pelvis plugging the orifice of the ureter. The cysts contained puriform urine. Nephrectomy was done. Patient cured.

Plate XII.

Even when the kidney is displaced downwards very much, the mid-vertical line rule usually holds correct.

c

c′

FIG. 2.

Illustration 3.—The shadow in Plate XII, marked *c′*, was cast by stone in the ureter, and that by *c* by stones in the dilated pelvis of the same kidney.

Clinical history.—A boy, aged 15, was sent me by Dr.

PLATE XII.

Shadows of phosphatic covered oxalate stones in the kidney and upper part of ureter.

Robert Grant, of Chatham, with symptoms of stone in the bladder.

Six weeks prior to admission into hospital he had had "influenza," and a week later he noticed the urine became thick and offensive; simultaneously pain was felt in the penis towards the close of micturition, but there was no frequency of the act.

The urine had sp. gr. 1003–1018, was acid, a faint trace of albumen, and some mucus was present. There had been occasional pain in the right loin.

As the boy had been twice operated upon in the country for stone in the bladder (supra-pubic lithotomy at age of six and litholopaxy at age of nine), the natural conclusion arrived at was that the stone had recurred in the bladder.

Cystoscopy.—No stone in bladder. Right ureteric orifice gaping and swollen. Left ureteric orifice healthy.

Radiography.—Disclosed a long stone in the upper part of right ureter and a blunt, branched, right renal pelvic stone.

Operation.—Right lumbar incision. Kidney found low down and fixed. Stone felt in pelvis of kidney and ureter. Both were removed through a cortical incision which was subsequently sutured. Boy healed. The stones proved to be phosphatic-covered oxalate of lime stones (Fig. 2).

Plate XIII.

As a radiographic illustration of the most marked downward displacement of a renal pelvis with a stone in it I give the following.

Illustration 4.—The oval shadow noticed immediately under the white arrow on the left iliac bone, reinforcing that which is cast by the bone itself, was cast by a large oxalate of lime stone in the hugely-dilated pelvis of a pyo-nephrosed kidney which had dropped within the pelvic brim. On removal of the stone the patient was again radiographed and the pelvic bone was proved to be normally clear.

Clinical history.—W. B. H—, aged 48, sent by Dr. Fred Pollard, Upper Tooting. From boyhood until thirty years of age he experienced a dull aching pain in the left loin (posterior costo-iliac space) and coffee-coloured hæmaturia was occasionally noticed. He was free from pain for fifteen years, then a return of the old symptoms took place. Latterly there has been a great increase in the severity of the pain, with fœtid urine and profuse hæmaturia. Urine: much fœtid pus; blood. Much microbic infection (*Bacillus coli communis.* Temperature normal or about 99° F. Cystoscopy: "Creamy pus pours from the left ureteric orifice. Both kidneys feel large; the left is fixed."

Left kidney was approached by the lumbar incision; it proved a pyo-nephrosis. Pelvis enormous; cortex thinned to a shell. Ureter small and under-strapped by irregular vessels running to the lower pole of the kidney. The pelvis contained a large oxalate of lime stone (Plate XIV), and the mucous membrane was covered with innumerable small patches of villous carcinoma (R. C. S. Museum).

Nephrectomy.—The patient healed well, but the growth recurred along the ureter and in the bladder.

PLATE XIII.

Shadow of an oxalate of lime stone (white-arrowed) in the pelvis of the left kidney which had become greatly enlarged and displaced downwards.

PLATE XIV.

An oxalate of lime stone which had caused symptoms of kidney mischief for 40 years. It cast the shadow seen in Plate XIII.

Plate XIV.

The stone weighed half an ounce; it was composed of oxalate of lime. It cast the shadow (white-arrowed) which is seen on Plate XIII.

(3) *Shadows about or along the mid-vertical line.*

A shadow placed upon or very near the mid-vertical has in my opinion an important signification. I believe it points to a stone in a hollowed-out calyx. The shadow of the cortex on the kidney edge, unless the organ is markedly loose or displaced, usually lies somewhere near the mid-vertical, hence stones in the cortex usually cast a shadow near or along the mid-vertical.

Now a stone in the cortex of a kidney is merely one which has developed or has become lodged in a dilated calyx, the dilatation absorbing by pressure more or less of the kidney structure. If then we can detect by position a cortical stone, we can infer that a calyx is dilated. Let me formulate a rule.

Rule 6.—Discrete shadows arranged along the mid-vertical usually denote stones in a dilated calyx, or in other words, cortical stones which are situated in the cortical substance of the kidney as distinct from those in the pelvis of the organ.

Example. — Plate XV shows four shadows (white-arrowed), arranged along the mid-vertical. They were cast by four separate stones in the lower calices of the kidney of a boy, aged 10, who had suffered all his life from incontinence of urine at night. There were no guiding symptoms, except that the urine was found to contain pus and to be loaded with bacteria (especially the *Bacillus coli communis*).

An X-ray was taken, because such urine in childhood often points to kidney stone.

The kidney was found much dilated and the tail (lower pole) was cystic. On cutting into this a cavity was discovered containing the four stones fairly near together.

The boy recovered from his enuresis, and the urine eventually became clear and sterile.

But the lesson to be learned from this case is not complete unless attention is drawn to the fact that the shadows of these four stones are widely separated in the

radiograph, whilst in the actual operation they were found together in *one* cavity formed by the dilated calyx or calices of the lower pole.

Rule 7.—Widely isolated cortex stone-shadows do not necessarily denote widely isolated stones.

Why are the shadows separate? Fluid urine in the dilated calyx generally intervenes between the stones, and as the X rays diverge the stone-shadows seem further apart than they really are.

Then separation of cortical shadows is an indication of fluid between the stones. We may go a step further, then, and suggest another rule.

Rule 8.—Small discrete cortical stone-shadows denote a kidney distended by back pressure. They do not mean widely isolated stones, but stones separated by fluid, either urine or puriform urine (hydronephrosis or pyonephrosis).

The operative indication of this is obvious. A novice in radiography would naturally expect widely isolated shadows along the mid-vertical to denote widely isolated stones in dilated calices, and the surgeon would anticipate, when called upon to operate for a patient whose radiograph showed many widely isolated shadows along the "mid-vertical," that he would have to split the entire kidney and examine many widely separated dilated calices.

These views are incorrect. Let me repeat. The stones which throw the shadows may be found quite near together *directly the fluid is evacuated* from the distended kidney, and this is an operative point worth bearing in mind. They may be in different calices adjacent to one another, but they are near together. Widely isolated cortical stone-shadows mean: (*a*) Past or present ureteric back pressure; (*b*) past or present dilated pelves and calices; (*c*) *slight* separation of stones by water in the hydronephrotic sacs or by pus.

Let me illustrate this point.

PLATE XVI.

Illustration.—Plate XVI is the radiogram of the left side of a lady who suffered from pain in the left loin, and whose urine contained muco-pus laden with amorphous phosphates, crystals of triple phosphates, and acid ammonium urate. A number of isolated shadows, D, C. B, and A, are noticeable. The upper ones D, C, B, lie on the mid-vertical, and were therefore diagnosed as stones in dilated calices. From the character of the urine they were thought to be phosphatic.

The lower shadow A is obviously in the ureteric area (inside the mid-vertical) and probably demonstrated a plugging stone in the ureter.

PLATE XVI.

Stone-shadows (D, C, B) along the mid-vertical, cast by stones in dilated calyces in the kidney cortex. A is a ureteric stone-shadow.

PLATE XVII.

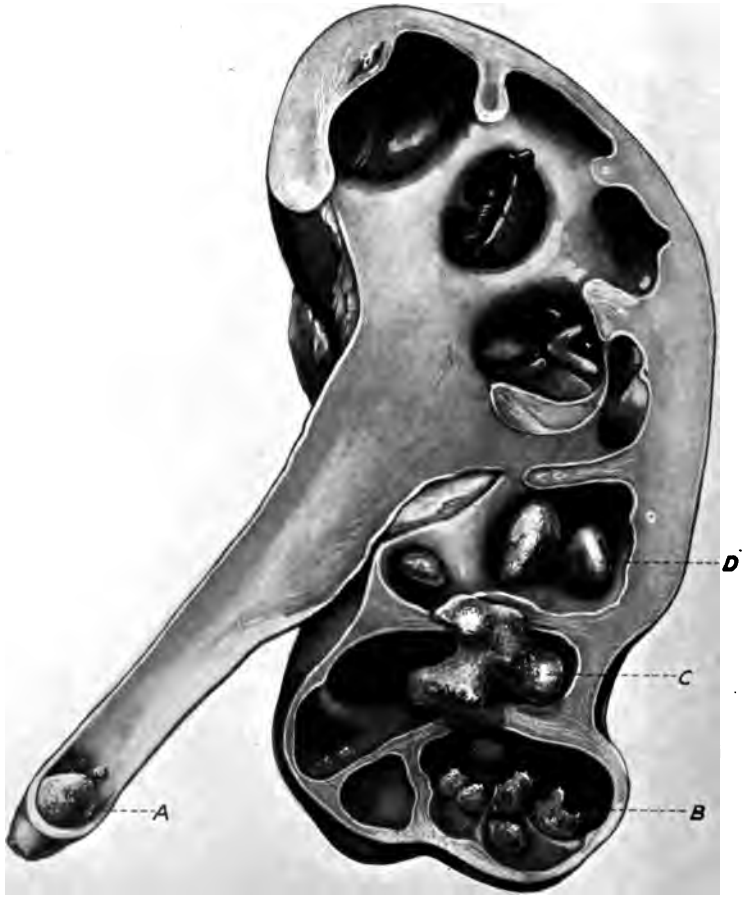

Section of a kidney radiographed (Plate XVI) before operation. B, C, D point to stones in dilated lower calyces, and A to an impacted ureteric stone.

PLATE XVII.

Left nephrectomy.—The kidney was extremely large and distended with urine. On cutting the kidney lengthways (Plate XVII), the shadows, D, C, B, were proved to be cast by phosphatic stones lodged in dilated calices of the lower half of the kidney, and the shadow A to be an oval phosphatic stone tightly plugging the ureter.

The extreme hydronephrosis, which is, of course, not evident in the collapsed and contracted specimen, and the tightness of the closure of the ureter by the plugging stone, rendered nephrectomy necessary.

The artist drew the specimen at once (Plate XVII), and it will be seen at a glance how exactly the actual is foreshadowed by the radiograph.

This subject is dealt with later, and the reader is referred to a demonstration in the operation theatre, which is described on page 45. Although this is not the place to allude to stone-shadows in the upper ureter, it will be noticed how much nearer the stone-shadow in the ureter of this case is to the vertebra. In fact it is a rule that—

A shadow inside the mid-vertical and in the lower half of the loin-space, the kidney being immobile and not displaced, is probably cast by a ureteric stone.

CHAPTER III.

THE VALUE OF RADIOGRAPHY IN SYMPTOMLESS STONE IN THE KIDNEY (LATENT RENAL CALCULUS).

In an extremely small proportion of cases it happens that a stone forms in the kidney quite insidiously, giving rise to symptoms which are unfelt or which may even pass unnoticed. In other instances, equally rare, a patient may complain of a sudden severe and typical renal pain, which followed directly upon a wrench or a blow or a prolonged unusual exertion. In such cases a routine radiograph may reveal the presence of the foreign body. It is therefore safer in any case to obtain expert radiography if the patient can command or obtain this method of examination. It will probably prove negative, but in the very smallest of possible percentages it will reveal a large latent stone.

Two illustrations of large latent stone with symptoms which had been noticeable for a very short period of time will suffice.

Illustration 1.—A lady, aged 22, was brought to me by Dr. Lennox Wainwright, of Folkestone, with the history that four months before a sudden pain had been felt in the left loin at golf. It was ascertained under rather severe cross-examination that there had never been any symptom before. There was a marked family history of cystinuria, and the patient was therefore brought to town at once for consultation and expert radiography. The right kidney was enlarged and movable, the left was insensitive and not palpable.

Plate XVIII revealed large calculi in both kidneys, and as the urine contained cystine these stones were diagnosed

PLATE XVIII.

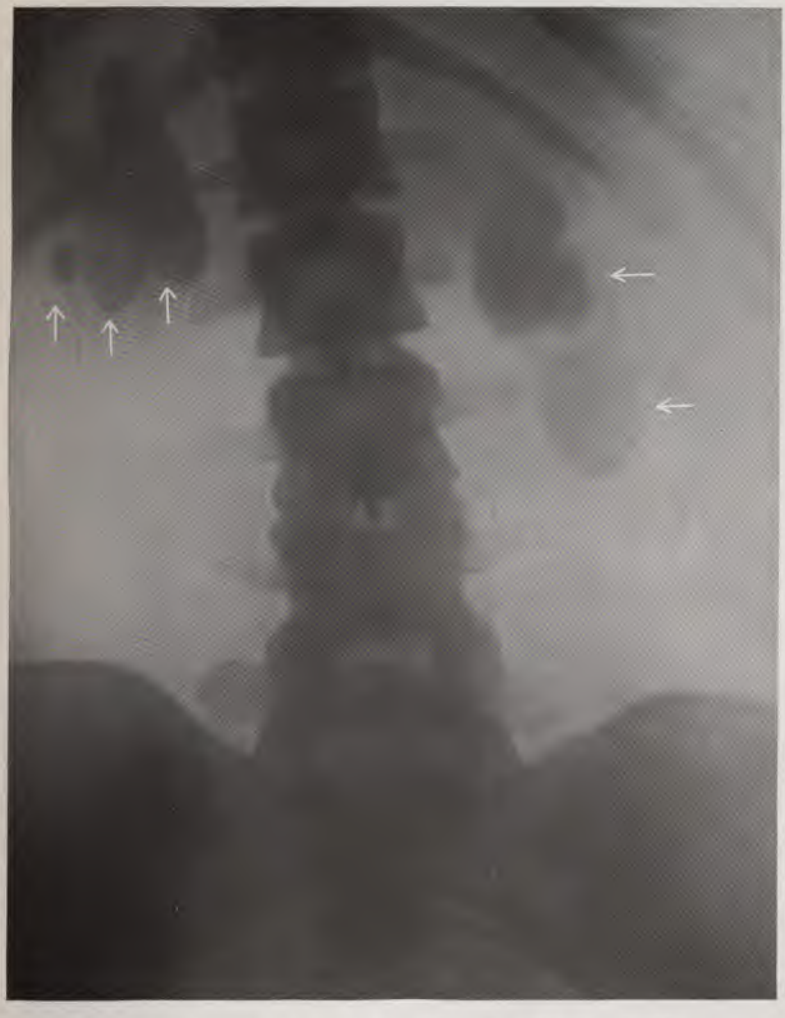

Shadows of latent cystine calculi (white-arrowed) in both kidneys.
(X-rayed by Mr. Lyster.)

to be cystine calculi. Mr. Lyster, who radiographed at my request, supplied me with a very admirable radiogram, and Dr. Lennox Wainwright kindly supplied me with the weights of the stones which were removed. Right kidney, transverse white arrows: 400 stones, one stellate and large, the rest small. Left kidney, vertical arrows : 14 stones, one stellate, the rest small.

Second Illustration of Latent Renal Calculus.

A man, aged 33, was sent me in September, 1902, by Dr. Cursham Corner, with *fixed,* dull aching pain in the left loin for fourteen days; the pain was not relieved by rest. The urine was thick with pus. There was no irritability of the bladder—no pain in micturition.

Fig. 3.—Six and a quarter ounce oxalate of lime stone removed from the kidney.

Neither kidney could be felt, but the left one was tender on deep pressure. He was X rayed in the routine, and a huge, dense, and sharp shadow was noticed occupying the left kidney area (Plate XIX). The patient was again cross-examined and admitted having had five attacks of left renal pain in his life—the same as he now experienced, but less severe in character. They had always occurred

PLATE XIX.

S = A very large oxalate of lime stone ($6\frac{1}{4}$ oz.) in the pelvis of the left kidney of a man.—(E. H. H.)

Engraved and printed by Bale & Danielsson, Ltd.

in the *left* loin. The first attack was twenty years ago; the last two years ago.

On opening the peri-renal area the kidney was found pushed high up under the ribs and firmly embedded in hard fat, and the pelvis occupied by a large stony mass. It was immovable like a sunk rock. All along the ureter, which was also fixed, but small and thickened, were masses of the densest adherent fat.

Finding the pelvis much inflamed and the kidney a mere shell, I removed the kidney and pelvis, being forced to utilise the scissors freely to separate the dense adhesions.

The stone (Fig. 3) weighed 6¼ oz.; it was a pure oxalate of lime and its shape corresponded to the shadow seen in the X-ray photo. Patient left the hospital for a convalescent home on the East Coast, but I heard subsequently he had had an attack of nephritis and that albumen had appeared in the urine.

CHAPTER IV.

STONE SHADOWS IN THE UPPER URETER—THE "LOIN-SPACE URETER."

A CONSIDERATION of the loin ureter is inseparable from the subject of the radiography of the loin space. I therefore briefly allude to it here, although later on (Chapter VI, p. 53) it will be again mentioned in conjunction with its more important section—the lower ureter.

The radiographic line of the loin ureter hardly ever varies unless the kidney is much displaced. It forms a vertical line which touches the tips of the lumbar transverse processes (Plate XXX, A, B). Any shadow typical of ureteric stone detected along this line should cause the operator to examine this section of the ureter before the kidney. I have already given one illustration of a stone-shadow in the loin ureter (Plate XVI A), and the rule runs thus:

Rule 9.—A shadow inside the mid-vertical and in the lower half of the loin space, the kidney being immobile and not displaced, is probably cast by a ureteric stone.

Two fallacies in shadow appreciation may be noted here:

The first lies in the blending of the shadow of a stone in the loin ureter with the shadow of the transverse process. If the shadow of the stone is faint, it will, under these circumstances, pass unnoticed. Here is a typical case:

A young man, aged 27, was sent to me by Dr. H. D. O'Sullivan, of Burton-on-Trent, with a diagnosis of left renal stone, which could not be detected with the radiograph. Mr. Harnack detected a slight darkening of the third lumbar transverse process (Plate XX, black-

Shadow of a stone (black-arrowed) in ureter blending with tip of transverse process of iii lumbar vertebra. This shadow has been rendered more apparent by the artist.

arrowed), and was positive that it represented a calculus in the upper ureter. He radiographed again, casting the X ray obliquely so as to dissociate the shadows, and the result is shown in Plate XXI.

In PLATE XXI

It will be noticed that the shadow of the ureteric calculus is now well away from the transverse process of the third lumbar vertebra, being dissociated, so to speak, from it by the oblique illumination.

I operated by a small vertical incision along the left loin, brought the ureter towards the surface, incised it over the little stone, stitched and replaced it. Patient healed well. The kidney area was not encroached upon or even examined.

Rule 10.—Any darkening of a transverse process necessitates another radiograph being taken—stereoscopically, if possible—the light being placed away from the mesial line on the side opposite to that of the darkened process.

The second fallacy in diagnosing a shadow to be a stone in the upper ureter consists in a shadow being cast by a small stone situated in the pelvis of a displaced or movable kidney. Bimanual examination will generally reveal the displacement, but it is an established operative rule that when in doubt examine the ureter first. If it is dilated let it be traced downwards before attacking the kidney.

It is needless to say that in the very obese neither the shadow of a stone can be obtained nor a diagnosis of movable kidney given.

In practice the use of the X-ray bougie is invaluable when a doubtful shadow is noticed in the track of the loin space ureter (compare Plate LXIX, p. 117).

PLATE XXI.

Shadow of ureteric calculus (black-arrowed) dissociated from the shadow of transverse lumbar process by oblique illumination. Compare Plate XX.

CHAPTER V.

THE INFLUENCE WHICH THE PRESENCE AND CHARACTER OF A STONE-SHADOW IN THE LOIN SPACE SHOULD EXERCISE UPON THE TREATMENT.

THERE is no doubt that the presence of a well-marked stone shadow in the renal area of a patient suffering from renal symptoms is very significant of the site and of the cause of the malady. In the majority of cases it may be held to justify the resort to operative interference, and if this is permitted it at once raises the procedure adopted from the rank of a mere exploration to that of the precise operation of nephro-lithotomy. But the character of the stone shadow should, I think, be of more assistance to the operator than this.

It can, and often does, afford the surgeon a rough prevision as to the difficulties he may encounter, and to the technique of the operation he might adopt with advantage. In other words, a stone shadow may *aid* in determining :

(1) The character of the **RENAL** incision.

(2) The extent of the necessary renal destruction.

(3) The position and extent of the **PARIETAL** incision.

These assertions will neither prove novel nor startling, nor perhaps unacceptable if they are examined carefully and in detail.

(1) A stone shadow may aid in determining the character of the *renal* incision.

There is as much tendency to follow a fashion and to be ruled by a fashion in operative surgery as in any other

vocation or walk in life. It is still, and it has been, the vogue for twenty years to drag a kidney suspected of harbouring stone on to the loin, to incise the cortex into the pelvis, to explore the pelvis with the finger, and finally to pass a bougie along the ureter into the bladder. All these steps are of the greatest importance in their way, and when they are necessary are of the greatest value, but in some instances they are unnecessary, and in a few they may be extremely detrimental, if not dangerous.

Bringing the kidney out on to the loin in women or very thin men is simple in the extreme, for the parietes are generally lax, the kidney is loose, the pedicle is long, and no injurious strain need accompany the manœuvre under these conditions. But in thick loins, such as we meet with in muscular men and fat women, it is far otherwise, and the strain on the pedicle which the drag exerts must in such cases be most injurious to the future health of the organ. In fixed kidney, or in those in which the organ is degenerated by fatty changes or deteriorated by inflammation, or in those in which the pedicle is implanted high in the upper pole or shortened and thickened by inflammatory fat, the procedure, viewed as a routine,[1] is not surgery but folly, if not madness.

The aim of true surgery is to remove a stone from the kidney with the least possible damage to the structure of the gland and to that of its collecting cavity, the pelvis; and this ideal, I contend, is more nearly attained with the assistance of knowledge gained from radiography of the kidney than by any other method of examination.

[1] I have operated upon the kidney over 500 times, and am convinced that this routine drag on an essential and highly sensitive organ is unwise. I have never employed the method if I could do what was necessary without dangerous dragging. I enlarge the wound and work, with my hand grasping the kidney *in situ*. Even in nephrectomy I tie and divide the pedicle, as often as is possible, with the kidney in position, and my results compare favourably with all published statistics.

STATEMENT.

Let it be granted that the radiograph demonstrates a small oxalate of lime stone in the kidney pelvis (Rule 3, page 9).

In many cases of small oxalate of lime stone of the kidney the renal pelvis may be incised and the stone removed without fear of a sinus resulting.

This can be accomplished by loosening the kidney—turning it slightly over on its long axis, so as to bring the hilum well into view, and whilst it is in this position, incising[1] the pelvis parallel with the ureter over the stone under the control of a head lamp. If the incision is clean and the urine is sterile there is no chance of a fistula.

Now oxalate of lime stones increase very slowly in size, therefore for five years they may remain small. They do not inflame the mucous membrane of the pelvis easily, therefore for some years they may be unaccompanied by microbic changes. Nor do they produce dangerous back pressure and dilated calices *early* in their course, for in the *earlier* part of their history they are usually to be found fixed near the orifice of the ureter and partially buried in the swollen mucous membrane. This position does not seem to mechanically occlude the pelvic orifice of the ureter so easily, so tightly, or so often, as a more movable stone or as a "nosed" stone growing into the outlet as a plug. A clean incision and a gentle removal often results in a very rapid recovery. Contrast with this a

[1] *Mem.*—Scraping through the pelvis wall with the finger-nail in cases of small, easily-located, attached oxalate calculi, where the kidney pelvis is readily reached in men—or easily dislodged in women—is, I think, to be deprecated; it tends to dislodge the stone and to drive it out of reach into a dilated upper calyx, from which the surgeon must remove it by a cortical incision. It leads to a ragged, lacerated wound, which, in healing, may warp the ureteric outlet of the pelvis, and which, in the course of a few years, may cause dilatation of the pelvis and pain from intermittent distension.

big incision into the abdominal wall, rough leverage of the kidney on to the loin, a cortical incision, the corresponding destruction of renal tissue by the inevitable blunt fumbling with the finger tip, the damage to the mucous membrane of the pelvis in scooping out a small stone partially buried in the swollen mucous membrane, the sharp hæmorrhage which must ensue, and the clot which must get locked up in the pelvis by the cortical sutures to form, perhaps, a clot nucleus for a further deposit, and an unbiassed surgeon will find the comparison unfavourable to the latter procedure.

Now the radiograph of a small oxalate in the pelvis of the kidney is characteristic of the disease, and in most instances the surgeon can expect, before he operates, if he adds clinical to radiographic data, to be able to incise the pelvis and remove the stone with but little destruction.

Rule 11.—A small oval or heart-shaped, sharply-defined shadow near the transverse process of the first or second lumbar vertebra in a patient who has had fixed loin pain and occasional hæmaturia in sterile, oxalate-of-lime-crystalled urine, should be operated upon by a lumbar incision, and if a pelvic stone is touched it should be removed through the renal pelvic route, if the kidney cortex feel healthy.

Statement.

A single stone shadow situated near the mid-vertical and well in the centre of the loin space indicates stone, associated with a more or less dilated pelvis, and with correspondingly hollowed-out calices. On seeing such a shadow the operator may anticipate :

(*a*) That his parietal incision may be extended with advantage forwards rather than backwards towards the spine.

(*b*) That the cortex of the kidney will need division and that probably that incision will involve part of the lower third.

(*c*) That nephrectomy may be necessary.

The first surmise (*a*) is not worth considering, except by a surgeon who is careful to do exact work with as little destruction of the parietes as possible.

But the second (*b*) is important. As long as a stone can be easily and gently brought through a clean incision in the pelvic wall, it is, I think, best to utilise this route; but such a route presupposes that there are no hidden cavities in the structure of the kidney concealing stones, for such hollows can rarely be reached or wisely or thoroughly emptied through a pelvic incision. Hence, when we have to deal with dilated calices a cortical incision is imperative. I have attempted to show that shadows which are near the mid-vertical are usually stones in dilated calices (p. 20); whether all the calyces are dilated by a ureteric obstruction or whether one calyx alone is hollowed out by obstruction to its pelvic outlet is, and must always be, uncertain on radiographic grounds. The fact remains that the nearer the stone shadow is to the mid-vertical the more certain is it that there will be distension of the calices.

Now general dilatation of the calices mean ureteric obstruction. Ureteric obstruction near the outlet of the pelvis means distension, more particularly of the calices of the upper and lower poles, for it is on the poles that back pressure works most destruction at first.

Now it will be found in such cases that the lower pole calices are usually distended more than the middle, and not infrequently if isolated stones are present in the calices at all, they are lodged in the lower in preference to the middle or upper. Moreover, distension of the upper pole drives the kidney downwards, so that usually, on cutting through the loin with a mid-vertical shadow, the surgeon will encounter the kidney low down. His finger will naturally be directed at first to the lower pole to ascertain if there is any "dimpling" of the cortex in this region.[1] This is generally present if the kidney be "dry," that is,

[1] I may remind the reader that dimpling of the cortex is the best indication to a thinned cortex—that is, to a dilated calyx.

if water or pus have not been pent up in the organ, so as to cause a general elasticity. The operator incises the cortex longitudinally over the dimpling area, enters and empties the calyx of its stones—if there are any there—swabs[1] it if necessary, and passes on into the communicating pelvis or neighbouring calyx, where presumably the stone which has cast the shadow is to be found. This being removed and the pelvis swabbed, the finger examines the opening of every calyx from its pelvic aspect. If any contain stones the cortex is incised again, but directly over the stone, and the stone removed through the incision. It is unwise to drag into the pelvis cortical stones through narrow calical orifices, for the interlobar vessels suffer.

[1] Do not use a lint swab, for the wool becomes detached, and may form a foreign body; a little compressed sponge, previously prepared, is wiser. Do not swab unnecessarily.

PLATE XXII.

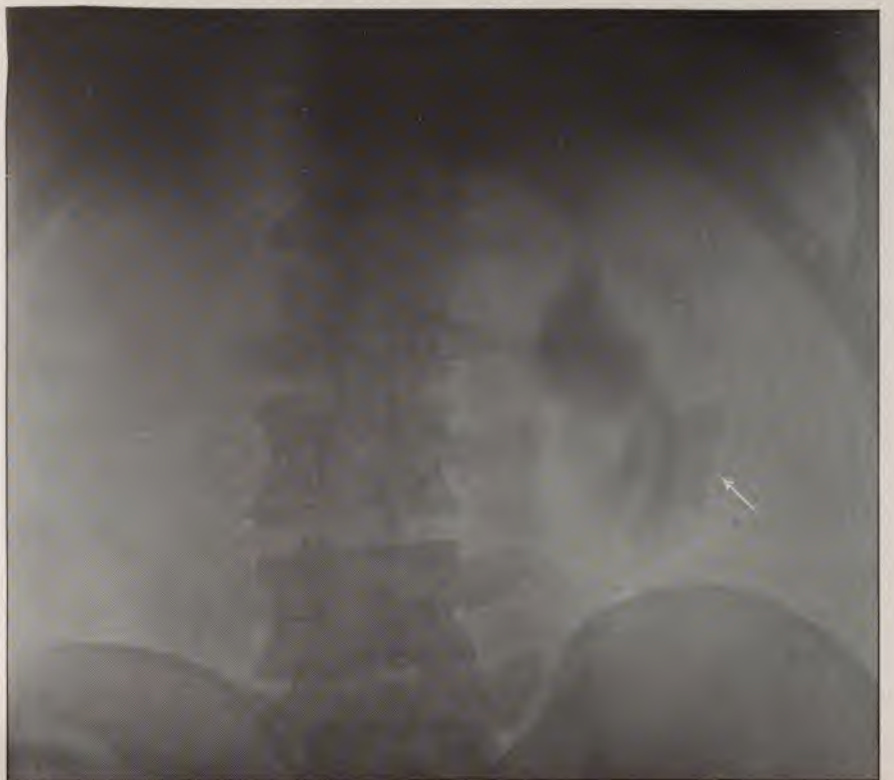

Stone-shadow with rays mid-vertical (white-arrowed) denoting distension of a lower calyx.

STATEMENT.

A stone shadow near the mid-vertical (well in the centre of the loin space) if accompanied by shadow rays, denotes distension of the calices and the formation of stones in them. The kidney may probably be preserved provided the urine be normal.

In working out this statement, which is of course merely an advanced condition to the one just mentioned, it may interest the reader to have a case in detail as it appears in my private notes (vol. vii, oper. p. 409, March, 1905).

The radiographic and clinical inferences are stated first, then the actual condition found on operation.

J. P—, a man, aged 50, was sent into the London Hospital from the out-patients with a history of eight weeks' right renal suffering, though he had had pain in the right side between the ages of twenty to thirty-eight. The urine was sterile; it contained no albumen, but oxalate of lime crystals. The radiograph disclosed a large oval shadow with three rays pointing *downwards* (Plate XXII, white-arrowed).

Inference: "The oval stone is sharply defined, its point tends downwards. This is probably a large pelvic oxalate of lime stone.

"The three ray shadows are in the lower pole, being near the mid-vertical. They are oxalate of lime calculi packed in dilated calices.

"As the lower calices are dilated, the oxalate of lime stone must have a nose and this must have produced a block of the outlet of the pelvis. The calices of the upper pole will therefore be dilated as well, but there are no stones in them; the pelvis will be thickened by irritation of the oxalate. As the urine is sterile, and as the stones are not phosphatic nor dendritic, it may be possible to save kidney, but any way I must obtain leave for nephrectomy."

Operation.—On entering the right loin an elastic, water-

distended kidney presented, it was easily separated; no adhesions, except at the upper and lower poles—a singularly free, healthy kidney. Working along the cortex towards the liver, my gloved finger plunged into a large thin-walled cyst, and much clear urine was evacuated. No stone in it; obviously a distended calyx cyst from the upper pole.

Exposed by blunt dissection of my finger point a slightly adherent, fat-covered pelvic wall. Thick; felt stone through wall, longitudinal incision and enucleation of a large, buried, oxalate of lime stone covered with spines like prickles of a musical box, the prickles having been buried in the swollen mucous membrane and the stone thus fixed in the pelvis. Introduced gloved finger tip into pelvis and felt for lower calyx. Easily detected opening into same, and on going further in, the finger found itself in a thin-walled, lower pole cavity containing stones. Cut on to finger through cortex and removed seven fawn-coloured stones, square like biliary calculi, sutured cortex wound. Cobbled up collapsed cyst of upper pole; left pelvic opening without stitches, in order to allow any blood-clot from the lower calyx to escape. Tube inserted into wound. *Did well.*

But all ray stones do not allow of sterile urine. Once the uratic or oxalate stones have induced pelvitis and phosphatic urine, the growth of the stone by phosphatic increase is rapid, and the repair less and less to be reckoned on as the hollowing and pyelo-nephritis increases.[1]

Rule 12.—A stone shadow near the mid-vertical (well in the centre of the loin space) is approached with the knowledge that the finger will have to explore dilated calices, probably of the lower and upper pole, the primary incision through the cortex being probably best in the lower pole.

[1] Nephrectomy may be needed. It is rare indeed for nephrectomy to be needed when the shadow is single, but it sometimes happens that a single stone plugs the pelvic orifice of the ureter so firmly that the kidney becomes a mere collection of useless cysts, and the replacement of the atrophied remains of the kidney after the stone has been removed may lead to an obstinate urinary sinus. Compare case, page 15, Plate XI.

PLATE XXIII.

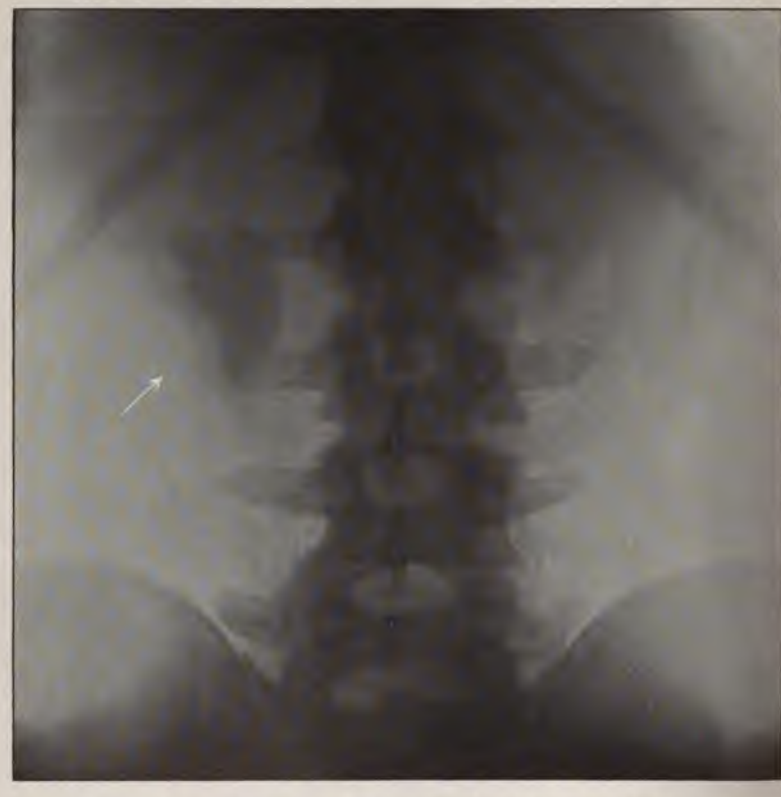

Triangular-shaped shadow (white-arrowed) with a "nose" pointing downwards.

STATEMENT.

A triangular shaped shadow in the renal region with the apex inclining downwards, though not accompanied by acute renal suffering, demands early operative interference, for it marks the first stage of the dangerous dendritic stone.

A triangular shadow[1] in the renal area is cast by a *phosphatic* mould of the renal pelvis. The apex, which may be termed the "nose," points downwards and inwards. This nose engages the outlet of the renal pelvis, and by inducing back pressure it causes hollowing of the calices and destruction of the parenchyma, *cf.* dendritic stone.

The more pointed the shadow of the nose the more urgent, in my opinion, is the need for operation.

The urine of such a patient is not always ammoniacal, but is usually amphoteric; it contains a little pus, always phosphates, and often coliform bacilli; but all the factors for renal destruction are present—a narrowing outlet, an increasing grade of pelvitis, rapid phosphatic deposition from the urine, and bacterial invasion.

It is true at this stage that the triangular stone can be removed by a clean cut through the pelvis without the formation of a sinus, but it is wiser to incise the cortex about the middle, remove the stone, and examine each calyx with the finger tip and sound for club-end extensions of the stone, for we can never be quite certain on radiographic grounds that club-ends fitting the calices are absent, as they do not readily cast a shadow.

In Plate XXIII is the triangular shadow cast by a pelvic mould-stone which formed after severe typhoid fever; the urine contained phosphates and typhoid-like bacteria. The stone was removed by a clean pelvic incision; the calices were just open. No stitches were used. Patient left at the end of the third week healed.

Rule 13.—A triangular-shaped shadow in the renal region

[1] Some of these shadows are shaped like a tiger's claw.

with a nose pointing downwards, and with phosphatic urine, renders early operative removal of a pelvic stone necessary before serious damage to the kidney ensues.

Let us now consider the second proposition.

A stone shadow may aid in determining the extent of the necessary renal destruction.

STATEMENT.

The greater the tendency of the shadow to exhibit rays (which often signifies a dendritic stone) the more certain it is that the kidney has suffered severely, and the operator should always be PREPARED for nephrectomy if the urine be phosphatic, puriform, and stinking.

A large shadow with ray extensions, if accompanied by phosphatic puriform bacterial urine, marks one of the opprobria of surgery—a neglected kidney stone, a stone which has been allowed to increase in size, producing dangerous diminution and often entire destruction of the kidney structure. The steps and processes involved in this destructive action are well known.

A stone in the renal pelvis irritates the mucous membrane and finally induces inflammation of that structure with production of septic pyelitis; phosphatic deposit rapidly enlarges the stone until it forms a cast of the pelvis. At this stage there are no rays visible (Plate XXIII), but as the stone becomes "nosed" and the nose plugs more and more effectually the outlet of the pelvis, back pressure is exerted more and more on the calices until they become hollowed. The next grade is rapidly reached, for branches from the primary deposit extend into and fill the dilated calices. These in their turn irritate the cortex and complete the destructive inflammatory changes of the parenchyma commenced by the original stone.

Now, it follows that the larger and thicker the shadow of the stone and the more marked its rays, the less the

value of the kidney as a secretory body, and the greater the danger to the patient if active pyelo-nephritis and toxin absorption are going on. It will be found that the best chance of life in very advanced cases is obtained by a clean nephrectomy. The policy of "giving the kidney a chance" in a highly developed dendritic stone or a renal mass stone with acute pyelo-nephritis has nothing to commend it. Let me give an illustration.

ILLUSTRATION OF A CASE IN WHICH NEPHRO-LITHOTOMY WAS PERFORMED WHEN NEPHRECTOMY WOULD PROBABLY HAVE BEEN THE WISER PROCEDURE.

I removed the branched stone, which was photographed and is reproduced in Plate XXIV, from the left kidney of a young man, aged 21. I carefully peeled the cortex off the stone and replaced the shell of the kidney. I did this because the other kidney was diseased and both ureters were blocked with stone. When I mention that the length of the stone was 6 inches, its breadth was $3\frac{5}{8}$ inches, and its weight was $6\frac{1}{4}$ ounces, it will be realised how greatly the kidney was damaged by the stone and by me in removing it, and how useless and even dangerous the organ must have been subsequently to the patient. I ought to have cleanly removed it.

He was relieved of his pain, but he quietly failed and died uræmic after eleven days, the urine at first averaging 70 to 100 ounces a day. On post-mortem I found the shell of the left kidney I had put back was much inflamed. The right kidney was enlarged and full of pus. There was a long stone in both ureters low down.

PLATE XXIV.

Large stone (natural size) from the kidney of a young man. Kidney peeled off stone and replaced. Death from uræmia.

PLATE XXV.

Shadow (black-arrowed) of a large branched and rayed phosphatic stone.

Here is another illustration, only with the foregoing lesson corrected.

Plate XXV shows a large branched and rayed stone shadow (arrowed) cast by a phosphatic-covered stone occupying the entire kidney.

Male patient, aged 26, was sent me by Dr. W. F. T. Burke, with a history of pyelitis of five years' duration; deep-seated localised pain in left loin, never hæmaturia. Great irritability of bladder if at work. Left kidney felt enlarged; loin muscles resistant. Urine 1020; pus.

Operation.—Kidney found to be a mere shell enclosing a dense mass of stone. Nephrectomy; healed by first intention.

Rule 14.—A large renal shadow with rays or branches indicating a dendritic stone with fœtid pyuria generally demands nephrectomy.

STATEMENT.

A stone shadow may by its mere mass give some idea of the magnitude of the renal destruction, and if severe pain is present it indicates the necessity for a clean nephrectomy, whether the urine be but little or greatly affected.

The mass stone.[1]—I have shown that when a large stone shadow gives the idea of distinct rays that this warns the surgeon he may have to perform nephrectomy, and must be prepared with permission to carry out this procedure. The advanced position follows as a matter of course. There are certain shadows which by their great size and irregularity leave no doubt but that all the tissue of the kidney has been replaced by stone or cretified material, and that removal of the entire organ is imperative if *the patient is suffering severe pain in that kidney.* Whether this huge and irregular shadow is cast by stone or cretified tubercle (page 119) or calcified hydatid is immaterial. The disease has destroyed the kidney, so that it is unsafe to leave the relics of the organ.

[1] For interesting fallacies of "mass stone" shadows see page 126.

One illustration of a mass stone and its probably correct treatment will suffice :

Plate XXVI shows a large irregular shadow (arrowed) grouped as far out as the mid-vertical.

A man, aged 30, was sent to me by Mr. Wilson, of our X-Ray Department, with this remarkable radiograph (Plate XXVI). The patient had suffered from pain in the left loin from childhood ; as a boy at school he had to raise his left leg on to his belly to ease the occasional pain which he felt in the left loin. He had passed blood ;

FIG. 4.—Stones removed from the kidney (Plate XXVI). Reduced in size.

is forced to sleep on left side. For some years now he has had constant pain in left loin with marked exacerbations. Radiograph revealed large dense and irregular shadow in renal area. The urine was very free from evidence of disease between the attacks of severe pain ; thus its specific gravity was 1022, it contained a trace of albumen and was faintly acid ; deposit only slightly excessive, and is almost wholly composed of crystals of stellar phosphate and bacteria. A very few hyaline casts. No pus.

Operation.—Directly the kidney was touched it was felt to be full of stone, and the cortex extremely thin. Here and there it was cystic. Nephrectomy without opening

PLATE XXVI.

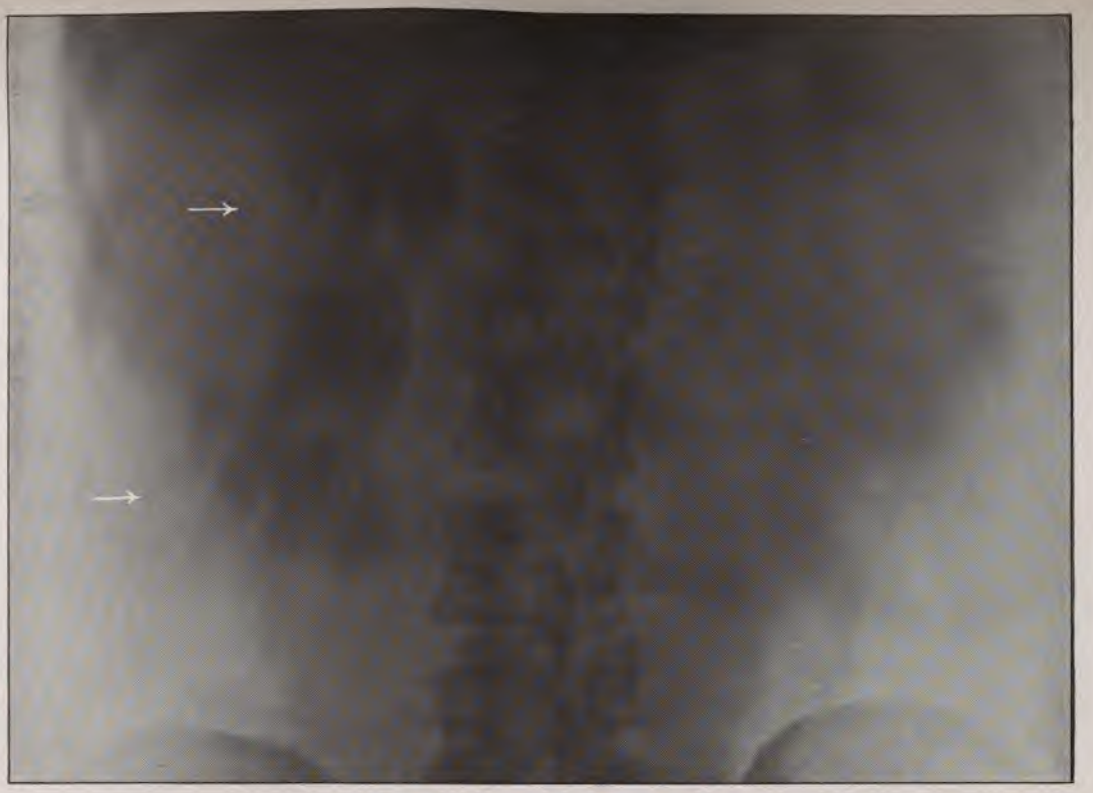

Deep shadow (white-arrowed) of a "mass" stone.

kidney. The stones were phosphatic covering uratic centres. They weighed 845 grains. (Fig. 4.)

Rule 15.—Prepare for nephrectomy if the shadow indicates a mass stone, and if severe pain is present.

STATEMENT.

The largest of known kidney stones may form without any pain or change in the urine. If there is no pain in a mass stone kidney it is, in my opinion, wise to leave them alone, for they are nearly useless and may not cause danger, but may even act as a nucleus for the deposit of phosphatic material as long as the kidney retains secretory power. When the secretory power ceases, the other kidney often takes on increased phosphatic output, and pain is experienced in the opposite kidney and pyelo-nephritis gradually supervenes. If any operation is undertaken it is wise to direct it against the last involved.

Rule 16.—Leave a latent renal mass stone alone if there is no pain experienced in the kidney.

AN OPERATIVE DEMONSTRATION OF THE OCCASIONAL ACCURACY OF THE X RAY IN REVEALING PATHOLOGICAL CHANGES IN THE KIDNEY PRODUCED BY STONE.

To sum up and to illustrate the teaching in the preceding pages, I gave a demonstration in my theatre (No. 5) at the London Hospital on September 19th, 1907. I quote it here verbatim:

"Some surgeons are rather disposed to under-value the use of the X ray in the diagnosis of urinary disease, because the method is only occasionally helpful in obscure cases, and because it is only an atom and not the entire molecule of clinical investigation.

"Others, again, do not seem to be guided by any rules for the intrepretation of the shadows which are shown on

the plate, and are quite content to accept the opinion of the radiographer, upon whom no responsibility should rest. No wonder such casualists are disheartened by the mistakes and failures which must necessarily occur. But surely there is a middle course? Let us admit many failures, some fallacies, and very decided limitations for the X ray, but let us employ it routinely when it is possible, and control its findings by operative work. Upon some such sound basis as this let rules of shadow interpretation be framed. If this be done, it will be found that the accuracy of clinical detail occasionally revealed by the shadows will be simply startling. I have given you certain rules which have guided me in my estimation of the character of X-ray shadows, and these are based on 1000 radiographs of urinary disease. I admit they are merely tentative, but I can give no greater evidence of my dependence on them than by utilising three or four of them this afternoon to draw for you on the blackboard a rough sketch of the left kidney of the patient who has just been brought into this theatre for operation. I only ask you to remember I cannot do this in every case; it is merely done now in this exceptional instance to show you how valuable the clinical evidence of a radiograph may occasionally prove."

PLATE XXVII.

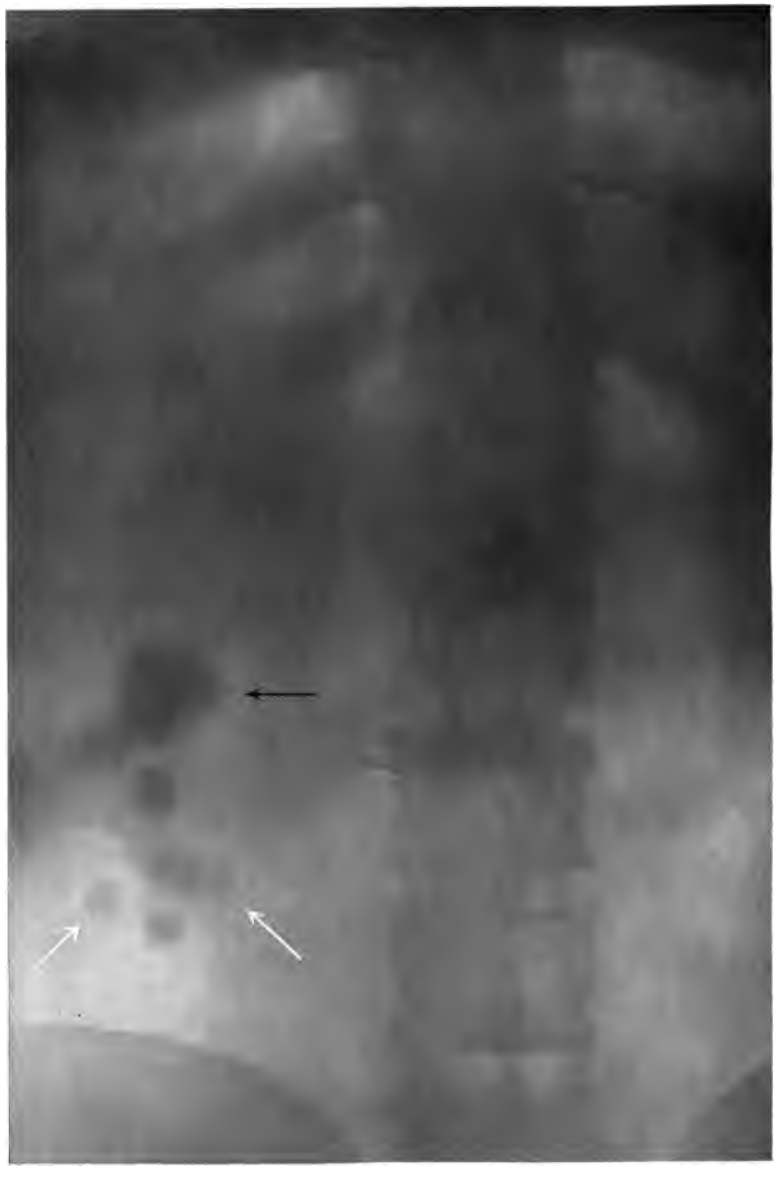

Shadow (black-arrowed) of dumbell pelvic stone in left kidney.
Shadows (white-arrowed) of stones in lower calyx.

"This young man is sent by Mr. Richard Whitelam, of Fulham, with a note that there is probably a stone in the left kidney, accompanied by serious destruction of that organ. The patient has but few symptoms. He has had a slight pain in his left loin on and off for ten years, which he ascribes to 'wind,' but his urine contains ¼ to ½ acid pus, which is obviously pyelitic, and on examining the left loin an enlarged but fixed kidney is distinctly to be felt. I will first sketch this kidney on the board, and show the changes in its contour and texture; I then propose to do nephrectomy, which I think will be necessary; if so, the section can be compared with the diagram; and finally I will explain to you the steps by which the clinical assumptions were arrived at.

"This radiograph (Plate XXVII) was taken by Mr. Harnack, of our radiographic department, and in the negative—for I do not believe in prints—you will see a number of shadows in the left loin area; these are cast by stones. The upper shadow is a fused shadow and it is like a dumb-bell in shape (it is black-arrowed). The lower group represent isolated stones, seven in number (they are white-arrowed). I assert from their position that they are in a dilated calyx of the lower pole of the left kidney. But I gather more than this from the radiograph: I realise the following facts, which I illustrate diagrammatically on the blackboard (Plate XXVIII): The left kidney is dilated by back pressure. This was originally a hydro-nephrosis, but as much pus has latterly appeared in the urine, I take it the kidney is now in a state of hydro-pyonephrosis. I therefore draw the kidney dilated, and write the diagnosis at the side. *You notice especially that I do not mark a dilated pelvis; there is no pelvis.* Secondly, I know the lower pole of the kidney is transformed into a smooth-surfaced, thin-walled cavity, which is merely a dilated lower calyx, and within it six smooth oxalate of lime stones are lying free. I mark this cavity off, and put six little circles to represent the stones in it. To prove to you the thinness of its wall, I

shall raise the lower pole in a few minutes to the surface of the wound, and you will see that the cortex will dimple under the slightest touch of the finger. This, of course, indicates thinning. To remind you, I will write 'dimpled cortex' opposite this area. Thirdly, higher up on the convex edge of the cortex in the lower middle part of the kidney is an independent projecting cyst. I draw a bulge at this spot and put 'cystic cortex.' On incising this I shall release a quantity of inodorous pus, and on inserting my finger I shall find another dilated calyx so over-distended as to form a projecting cyst. The mouth of this cyst-forming calyx is blocked by the knob end of an oxalate of lime stone. I mark this stone, drawing two little curved lines from its neck. Fourthly, higher up again the cortex of the kidney may be thicker, but the upper pole is also transformed into a cavity which contains no stones. I cannot say if there is a real cyst at the upper pole or not; I can, however, assure you that it is extremely dilated, so I will just dot the convexity of the pole to denote this. Lastly, an oxalate of lime stone is in the pelvis, and it has a nose or conical projection in front. I know that this nose of the stone has blocked the pelvic outlet, and back pressure has resulted. It is, in fact, 'a plugging stone,' so I write this at the side. I may finally add that the oxalate of lime stone in the pelvis of the kidney is somewhat dumb-belled in shape, so I draw it of this shape; its surface is rough with phosphatic deposit."

PLATE XXVIII.

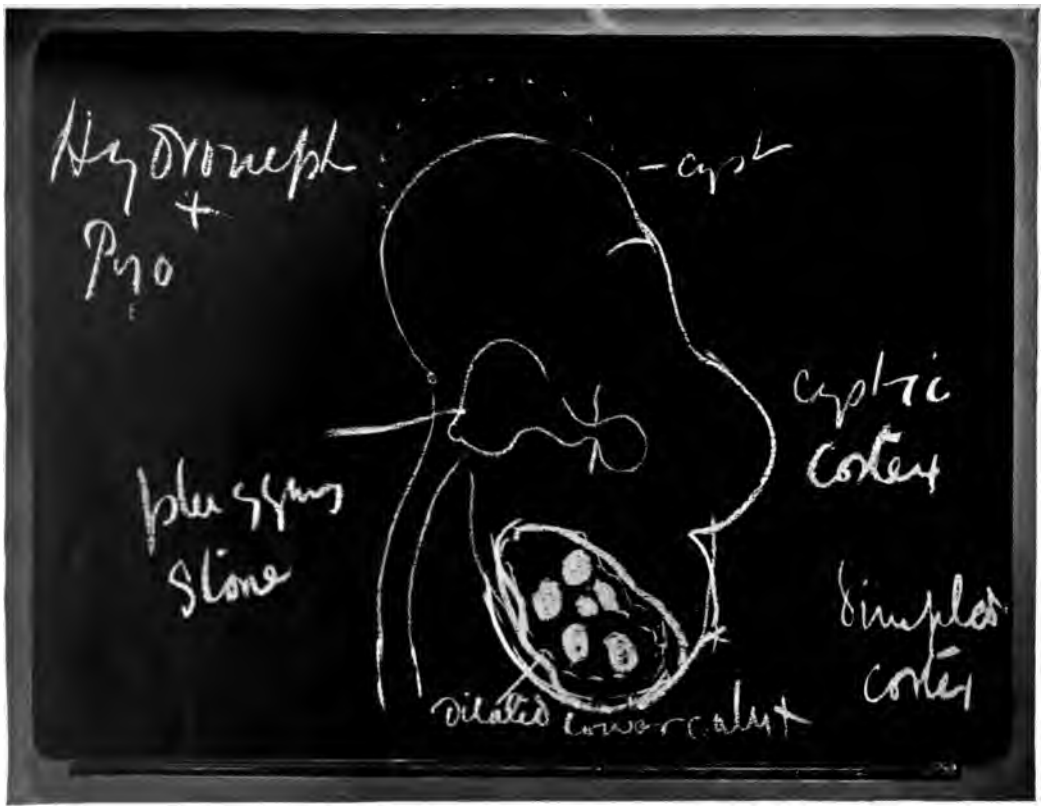

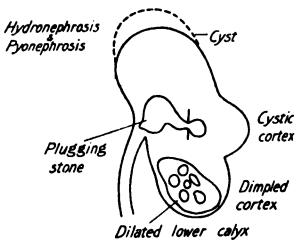

Blackboard diagram, drawn before operation, of condition of left kidney as revealed by preceding radiograph (Plate XXVII).

PLATE XXIX.

Drawing of half left kidney removed from case of which Plate XXVII is the radiograph.

The operation was now carried out. The cortex was exposed, and the lower lobe was raised and shown to dimple under the pressure of the forefinger; higher up the projecting cyst was demonstrated, and 6 oz. of inodorous pus and urine were sucked out from it. Nephrectomy being found necessary, the organ was removed. After the wound was closed the kidney was cut lengthwise for demonstration (Plate XXIX). The changes in it were proved to be as depicted in the diagram on the board. The kidney was dilated greatly in all parts, the cortex being extremely thin. The lower pole was much hollowed, and one calyx contained five instead of six stones, the sixth being found in an adjacent cavity. An oxalate of lime stone was found in the pelvis; it was firmly gripped by the pelvic mucous membrane, its front projection (the nose) blocked the ureter, and the one towards its posterior aspect (a boss) was tightly embraced by the mouth of a deep calyx, and the back pressure exerted by it had created a cyst which projected from the cortex of the lower middle third of the organ. The upper pole of the kidney was much dilated, but there was no true cyst projection, and there were no stones in this portion of the organ.

"Now, what clinical and radiographic data gave me such confidence that I could draw exactly beforehand a condition of kidney which was unrecognisable to touch? Permit me to enumerate them.

"The shadows in the left loin space of the radiograph are very sharp, and the man is young, therefore they are oxalate of lime stones (Rule 8, page 9). There is acid pyuria, hence they will have a slight coating of phosphate of lime (clinical rule).

"The six isolated shadows are grouped near the mid-ileo-costal vertical (the mid-vertical line), hence I conclude they are in a calyx (Rule 6, page 20), and as they are seen below the main large shadow, which must be a stone in the pelvis, they must be in a calyx of the lower pole. The shadows are clearly separate, hence there is fluid between

them (Rule 8, page 21), and thus I know the kidney is distended with fluid. The urine contains ¼ to ½ pus, acid and inodorous; I then know I have a hydro-pyonephrosis. A distended lower pole means ureteric block or pelvic outlet block; but when I notice a large dumb-bell shadow above the isolated collection I realise at once that this is a pelvic oxalate, and in order to produce distension of the kidney it must have a nose or projection upon it, and that this nose must be grasped firmly by the pelvic outlet. With such an extreme back pressure the upper pole nearly always suffers in the same way as the lower pole. Hence I mark the upper pole as dilated. But how do I know there is a general distension? The shadows of the stone are well in the loin space, and not high up under the ribs; moreover, the kidney can be felt bimanually, and it is fixed, not mobile—therefore it is displaced. A displaced fixed kidney in a young man means a distended kidney (clinical rule). There are no shadows in the upper pole; hence no stones are in the upper pole. But how do I know that there is a cyst projecting from the cortex of the lower middle third? This is as easy of inference as the rest of the picture. I notice a boss projecting backwards on the stone shadow in the pelvis; clinically I recognise that the outer part of the dumb-bell must be tightly fitted in the mouth of a deep calyx. With such a tight fit there will be no exit for the urine in that calyx, and a cyst must be formed and must project."

The blackboard was photographed by Mr. Harnack (Plate XXVIII), and the kidney was then drawn by Mr. Shiells (Plate XXIX).

The third and last proposition submitted to the reader on page 31 has now to be considered.

3. The position of a stone shadow *may* determine the position and extent of the **PARIETAL** incision.

I have attempted at the commencement of this chapter to show that a clear radiograph may afford the surgeon who can correctly interpret shadows, a fair idea as to

whether a renal operation for stone can be urged or not; also that it may indicate the difficulties of the operation, and, lastly, that it may give the operator a clue as to whether it is wiser to cut through the pelvis or approach the stone through the cortex, or even remove the kidney without opening the organ at all.

But a clear radiograph may convey even more than this: it may disclose a stone shadow in the *lower* ureter, and thus divert the attention of the surgeon from the aching kidney altogether and direct it to the necessity of freeing the *lower* ureteric channel. This latter attempt must be made through an incision different to that employed by the surgeon for reaching the kidney. Indeed, in many instances expert surgery cuts directly upon the lower ureter and does not meddle with the kidney at all.

One of the most distressing failures in urinary surgery consists in the operator cutting into a kidney and mutilating it, perhaps irreparably, in order to find a stone which has long ago left that organ and travelled down the ureter. And yet this must happen in 30 per cent. at least of all cases exhibiting reno-ureteric stone symptoms if the X-ray expert is not called upon to help in the diagnosis.[1]

[1] The records of stones actually removed from the kidney or from the ureter at the London Hospital since the introduction of radiography are as follows. I introduce them merely to show how frequently ureteric stones are found:

Years.	Stones from kidney.	Stones from ureter.	Total.
1899 and 1900	15	—	15
1901	12	1	13
1902	17	2	19
1903	30	1	31
1904	19	8	27
1905	30	10	40
1906	28	10	38
1907 (up to end of August)	12	13	25
	163	45	208

Any impartial critic will concede that the first few years of a new

That he can guide the urinary surgeon with a precision unattainable before the introduction of the method is without cavil. In fact, it seems to me that the service rendered to both patient and surgeon by an expert radiographer when he accurately defines a stone in the lower ureter is an obligation which both should find difficult to discharge.

Now, it is a self-evident truth that ureteric stones, and stones located in a congenitally displaced kidney (Dystopia renis)[1] must be approached by a parietal incision, differing from that used for exploration of the kidney. Hence we can assert that the position of a stone shadow may determine the position of the parietal incision. The practical question which now arises is: What is a typical ureteric stone shadow? and the answer to this is sufficiently important to demand a separate chapter.

method are mainly spent in discovering its limitations and errors as well as its possibilities. The figures of the first five years of the use of the Röntgen rays in urinary surgery in my private work may be ruled out, and I feel this should also obtain with the public work at the London Hospital. It will then be seen how frequently in the last four years ureteric stones have been discovered and operated on.

[1] *Cf.* Casper, 'Handbuch der Cystoskopie,' Leipzig, 1905, p. 216, Fig. 82. The subject is too rare for consideration here.

CHAPTER VI.

THE CHARACTER OF SHADOWS CAST BY STONES IN THE LOWER URETERIC CHANNEL.

BEFORE a shadow in the bony pelvis-area can be accepted as suggesting the presence of a stone in the lower ureter it should fulfil four conditions:

(1) The shadow should be in the line of the ureter.

(2) It should be oval or more or less elongated in outline.

(3) Its long axis should be directed downwards towards the bladder.

(4) The clinical history should reveal intermittent renal suffering.

1. THE SHADOW SHOULD LIE ON THE LINE OF THE URETER.

It is still taught that a stone descending the ureter from the kidney is more usually arrested at one of the three points where the ureteric channel is narrow. "Either just below the kidney (two centimetres below the commencement of the ureter), or where the ureter enters the wall of the bladder, and especially at its termination on the mucous surface of the bladder; or, thirdly, where the ureter crosses the brim of the bony pelvis."[1]

This is probably true if the stone has been long impacted, for it will increase in size, whilst it halts at the narrowings of the channels. It is also true that

[1] Morris, 'Surgical Diseases of the Kidney and Ureter,' vol. ii, p. 449.

operative findings at first corroborated this view,[1] but the surgeon of to-day and of the future must not depend on these typical positions, though he should bear them in mind, for stones are now removed much earlier in the course of the case, before they are finally arrested, and they are often, therefore, found in positions which do not represent the narrowings of the ureter.

[1] Forty-five cases of ureteric stone are tabulated by Morris (*op. cit.*). In nineteen the stone was found within two inches of the kidney, in fifteen it was just before or where passing through the vesical wall, and in eleven at or about the brim of the true pelvis.

PLATE XXX.

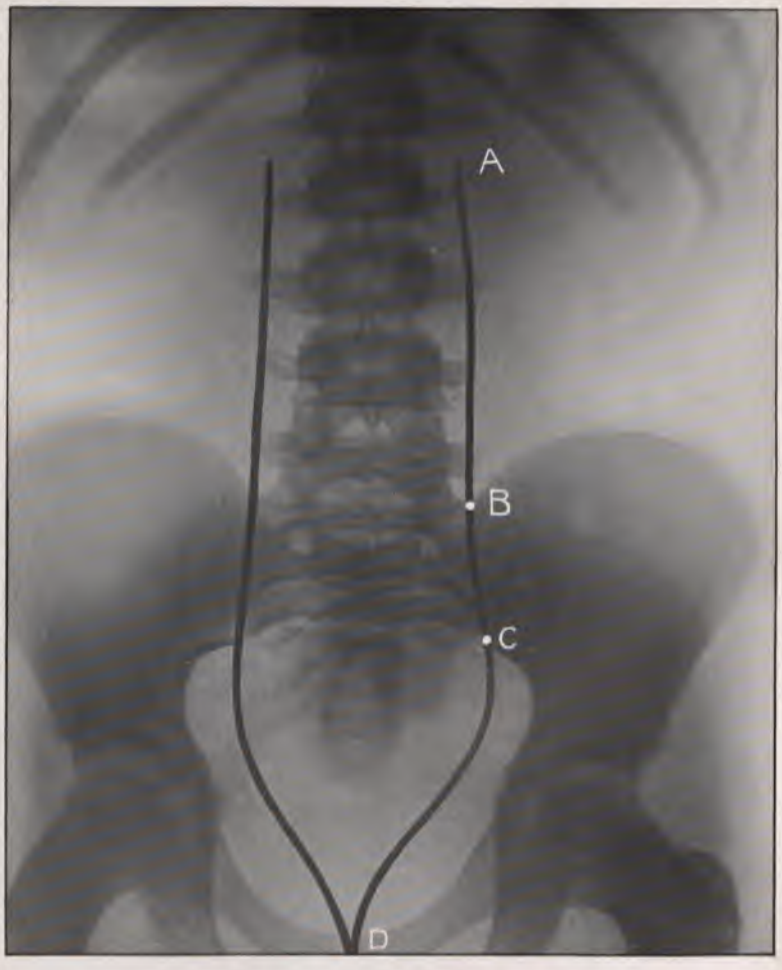

Diagrammatic divisions of the radiographic shadow of the ureter.

The entire X-ray line of the course of the ureter should be closely studied and a clear idea obtained of shadows which are distinctive of ureteric stone and of shadows cast by other substances, and therefore suggestive of mimicry.

Radiographically the ureter is divided into three parts, if the lamp be placed mesially (Plate XXX):

(*a*) That section which traverses the clear loin area—the loin ureter (A. B.).

(*b*) That which courses over the shadow cast by the wing of the sacrum—the sacral wing ureter (B. C.)

(*c*) That which crosses the clear area enclosed by the shadow cast by the pelvic brim—the pelvic cavity ureter (C. D.).

(*a*) *The loin ureter line.*—The line of the loin ureter (A. B.) hardly ever varies unless the kidney is much displaced, and this latter condition can be estimated bi-manually. It forms a vertical line which touches the tips of the lumbar transverse processes. Any shadow typical of ureteric stone detected along this line should cause the operator to examine the ureter before the kidney.

(*b*) *The sacral wing ureter line.*—There is a broad transverse ribbon of shadow thrown by the sacral bone where it articulates with the ilium. The shadow line of the ureter (B. C.) passes over this area, and a stone in the ureteric channel here must cast a shadow which would blend with that of the bone. It may be due to the paucity of numbers, but I have not seen a large ureteric stone shadow upon this sacral wing, though I have met with them above and below. I may here mention that just below the edge of the sacral wing shadow or above it there are often large, irregularly rounded shadows met with, which are cast by calcareous glands, either of the meso-rectum or mesentery, or even by those belonging to the sacral or lower lumbar group, and these are often mistaken for stones (*vide* fallacies, page 105).

(*c*) *The pelvic cavity ureter line.*—This line is easy enough to trace on a radiograph. The reader should

glance at Plates XLVII, XLVIII. In these the ureters have been filled with shadowgraph bougies, and their course, radiographically, is represented by lines from the sacral wing to the pubic symphysis with a slight curve outwards.

It is, however, difficult to estimate on radiographic grounds the exact position of the different sections of this tube, therefore it is difficult to judge correctly whereabouts in the pelvic ureter is the stone which casts an obvious shadow.

To a casual observer it would seem easy enough to locate a stone shadow in such a ureter by merely measuring the distance between the shadow and the nearest fixed bony point, such as the sacrum, ischial spine, or pubic symphysis.

A moment's reflection corrects this view. The straight line seen in the radiograph represents a rod which inclines backwards and downwards in a big curve. It is, therefore, a shadow compounded of many super-imposed and coalescing shadows which have been cast by different sections of a curved rod, hence the exact position of any point in such a curve can only be ascertained with difficulty. The exact location is best accomplished by stereoscopic radiography; or, more practically, by passing a measured ureteric bougie[1] up the ureter till it touches the stone.[2]

[1] They can be obtained marked in inches or centimetres at Bell and Croydon's, 50, Wigmore Street.

[2] They are passed under control of the head-lamp in the female or cystoscope in the male, and the operator calls out the markings, one inch, two inches, three inches, and so on as he sees the marks disappear up the ureter until the point of the bougie is arrested by the stone in the ureter. A rough estimate is thus obtained as to where in the pelvis is the stone and as to how far it is from the bladder.

PLATE XXXI.

Skiagram of rounded stones in the ureters of a young man. Operation. Recovery.

2. The Shadow should be Oval or more or less Elongated in Outline.

The shape and density of ureteric stone shadows can be better appreciated by a series of typical cases.[1] Suffice it to say a ureteric stone shadow is most frequently oval or of an elongated form : that it is rarely *round.*

Clinicians may very pertinently remark that many of the uratic calculi which descend from the kidney are round. That fact may be admitted; but uratic calculi are rapid in their transit, and are not often, therefore, submitted to radiography, and when they are, they rarely cast a shadow, and thus remain undetected. Most of the oxalate of lime stones are elongated, and the prolonged stay[2] which such bodies make in the narrow tube cause them to accumulate material at either end, and thus they tend to assume an oval shape.

A rounded, irregularly bordered shadow always should raise a suspicion of a cretified gland, or a sharp, round, small shadow should suggest a phlebolith, or a small irregular shadow a patch of atheroma : more on this point will be said in dealing with the fallacies of ureteric shadows (page 74).

I have come across large, round stone shadows in the lower ureter, but I am convinced that they are uncommon. Still, as this does occur I give the following case of round oxalate of lime ureteric stone shadows. Plate XXXI shows :

Symmetrical shadows (white-arrowed) which were found in a patient, aged 18, who complained chiefly of pain in the glans penis after micturition, and occasional pains across the back. Hæmaturia had been noticed.

[1] In describing the shadowgraphic bougie ('Brit. Med. Journ.,' June, 1905), I gave a valuable, and, I believe, an original hint to radiographers, to fill the bladder and even the bowel with air. This clears up a large part of the pelvic area (*vide* Plate LVIII) and renders stone shadows sharper.

[2] I have alluded to these cases in Chapter VII.

The cystoscope showed the calculi to be in the lower ureteric canals, for the ureteric orifices were swollen and the mucous membrane lining the mouth of these channels was prolapsed.

I removed both stones by the perineal route, working between the bladder and rectum and opening the ureters over the impacted stones: the patient recovered and reported himself as well five years later.

3. The Long Axis of the Shadow should be Directed more or less Downwards towards the Bladder.

If we except the rarely-met-with round ureteric shadow we can assert that the long axis of a ureteric stone almost invariably points more or less downwards. I say more or less, for the longer a stone is in the tube, the larger and heavier it becomes. Its increased weight (for it may weigh up to half an ounce in my experience), together with the pressure of the urine above it in the distended ureter, may cause it to sag to one side.

Very occasionally an oval bladder shadow of fair size may appear like a ureteric stone shadow which has sagged obliquely (Plate XXXII), but the clinical history is quite sufficient to decide upon the exact position of the stone.

Presuming, then, the radiographer to be in doubt as to whether a medium-sized oval stone is in the ureter or in the bladder, all that is necessary for differentiation is the clinical history and radiography under varying postures. A ureteric stone nearly always has a clinical history of reno-ureteric pain, and a bladder stone *moves* but a ureteric stone is invariably fixed.

An oval stone shadow placed *transversely* at any part of the pelvic area should raise a suspicion of a stone in the bladder, or walls of the bladder.

The *transverse* shadow may be thrown very near the pubes, and then it is characteristic in position, size, and shape of a vesical calculus, and the question of ureteric

PLATE XXXII.

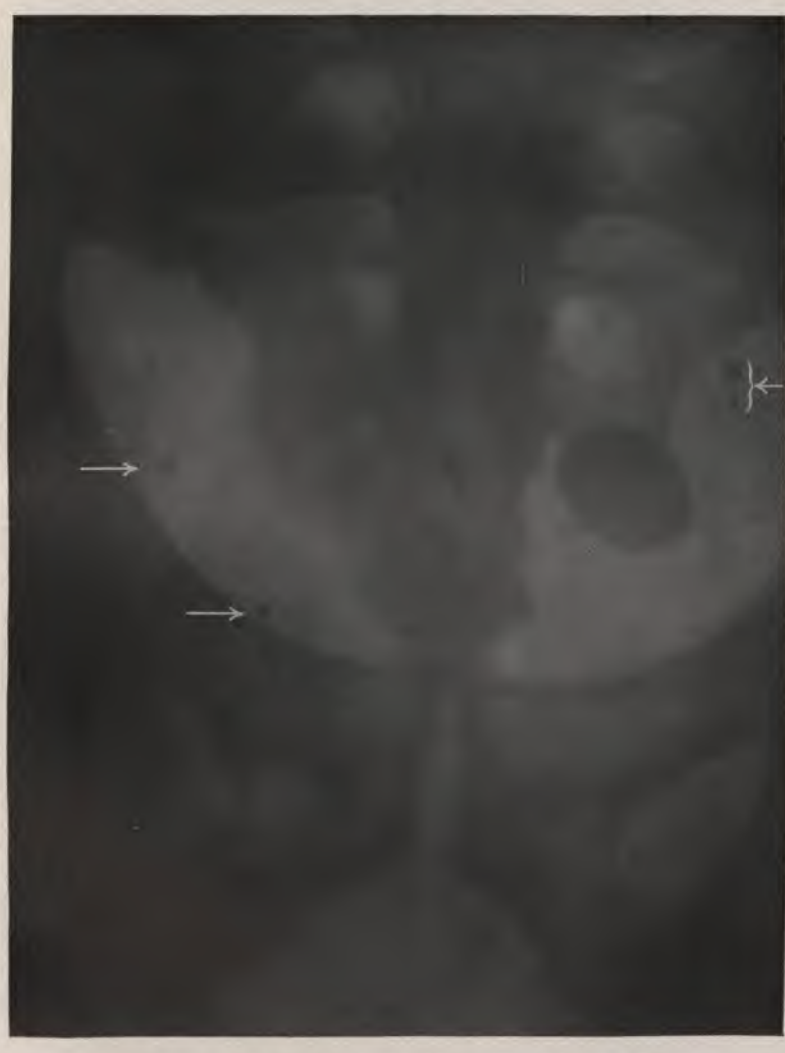

Shadow of a large oval stone in the bladder. The phlebolith shadows are white-arrowed. (Thurston Holland.)

calculus is not raised, but an *oblique* oval shadow cast by a bladder stone may be occasionally seen high up near the sacrum. Such are chiefly seen in cases where a stone is carried up and balanced on the top of a very much enlarged prostate. One illustration will suffice to convey the meaning and lesson of this little fallacy.

PLATE XXXIII.

Plate XXXIII shows the shadow cast by an oval vesical stone which was propped high up in the bladder by an enormous prostate. The shadow is somewhat obliquely placed, but it is unusually high up in the pelvis near the sacral promontory.

Clinical history.—From a gentleman, aged 62, who had had symptoms of an enlarged prostate for ten years, and had been absolutely dependent on his catheter for eight years. Supra-pubic lithotomy and prostatectomy. Sound recovery.

Rule 17.—A small shadow in the bony pelvis-area is suggestive of stone in the lower ureter if it is in the line of the ureter, and is oval or more or less elongated, and if its long axis is directed more or less downwards towards the bladder, and if the clinical history of ureteric stone is in accordance.

Rule 18.—A transversely placed large oval shadow in the bony pelvis-area is characteristic of bladder stone.

PLATE XXXIII.

Obliquely placed oval shadow (white-arrowed) of a bladder-stone placed very near the sacrum.

PLATE XXXIV.

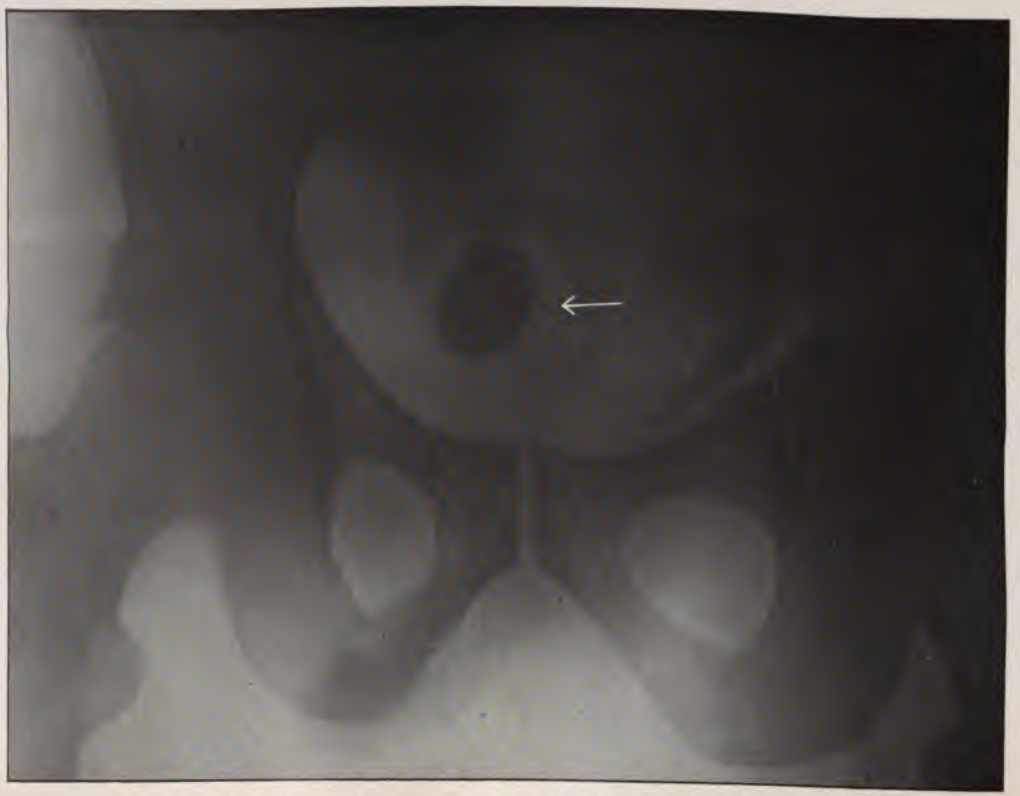

Bale & Danielsson, Ltd.

Shadow of oxalate of lime stone (white-arrowed) in lower ureter, of 40 years' history.

A Series of Typical Renal Calculi in the Pelvic Area.

As a better idea of the appearance of ureteric stone shadows can be obtained by examining various types, I have selected the following from my collection.

Plate XXXIV shows a shadow cast by a large oxalate of lime stone in the right ureter, midway between the pelvic brim and the vesical orifice of the ureter. The shadow is dense, oval, its long axis points more or less downwards,

Fig. 4a.—Actual size of stone of Plate XXXIV.

it was removed from a patient, aged 60, who had had right renal symptoms for forty years.

Operation.—November 24th, 1904. External iliac artery incision, peritoneum lifted, ureter found to be greatly enlarged and thickened. Stone discovered lying about midway between the pelvic brim and the vesical orifice of the bladder. Ureter incised. Stone enucleated and with it a fibrin and muco-pus bed. Sutures, primary healing, patient recovered.

Photo, actual size (Fig. 4a).

PLATE XXXV.

F. M—, aged 30, was sent me with an X-ray diagnosis of stone in the bladder. I cystoscoped because the shadow of this stone on the radiograph (Plate XXXV) was long and its axis almost vertical, so that I felt certain it was ureteric. There was no stone in the bladder, and obviously the calculus was lodged in the ureter. The cystoscope showed that the left ureteric orifice had an appearance characteristic of ureteritis with ureteric calculus arrested low down. The opening was fringed like the end of the Fallopian tube in colour and shape. I opened the peritoneal cavity over the left rectal sheath, and inserting my fingers pressed the stone up along the ureter until I had brought it above the pelvic brim. I now cut extra-peritoneally as if for tying the iliac artery, and when the hugely dilated ureter came into view I opened it longitudinally, evacuated a quantity of clear urine, put in forceps and pulled out a large oval oxalate of lime stone.

The ureteric orifice was then stitched, and the extra-peritoneal wound closed except for a drain-tube, finally the vertical intra-peritoneal incision was closed. The patient made an uninterrupted recovery.

PLATE XXXV.

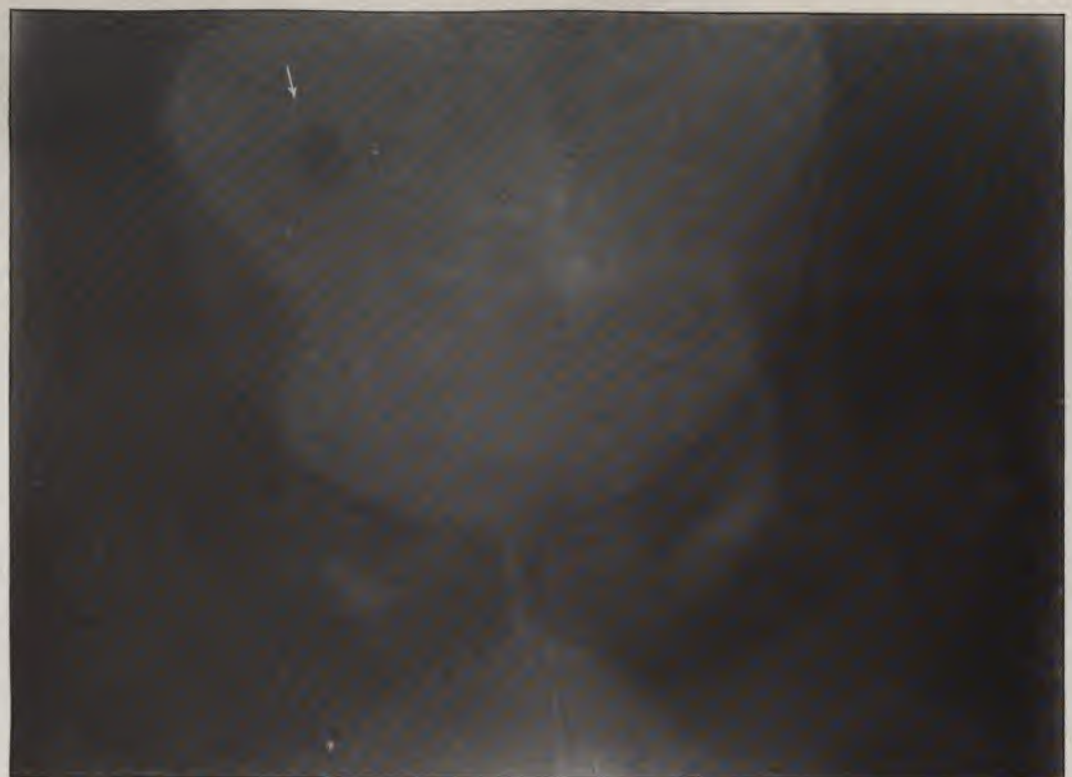

Shadow of an oxalate stone (white-arrowed) in lower ureter.

Bale & Danielsson, Ltd.

PLATE XXXVI.

Shadow of an oxalate stone (white-arrowed) low down in ureter.

PLATE XXXVI.

An oxalate of lime stone shadow (white-arrowed) low down in ureter (Plate XXXVI).

A patient, aged 28, was sent me by Dr. Spinks, of Bloomsbury, with ureteric stone symptoms.

Clinical history.—He had passed blood at the age of eleven, and continued to do so intermittently until a surgeon removed a polypus from the bladder three years ago. He had also definite "back pressure" symptoms of septic renal pain, and absorption.

Operation.—May, 1905. Oval calculus of calcium oxalate removed by usual incision. Rapid healing. Cure.

CHAPTER VII.

THE INFLUENCE WHICH THE CHARACTER OF A URETERIC STONE SHADOW IN THE BONY PELVIS-AREA MIGHT EXERCISE IN MODIFYING OPERATIVE MEASURES.

Is it possible that the character of a ureteric stone shadow in the lower ureter can afford the clinician any hint as to appropriate treatment?

I put this question without prejudice, for I believe that occasionally a clear radiograph can indicate a wise line of treatment.

It will be conceded, if the shadow of the stone in the lower ureter be oval, large, and very sharply defined, and the history long, dating from childhood, as in the type cases I have just recorded, that no surgeon could feel justified in advising palliative measures. If the kidney is to be saved at all it must and can only be by the operative restitution of the normal ureteric calibre and of free kidney drainage.

Moreover, if there be *no* shadow of a stone in a clear radiograph of a patient suffering from renal colic and the smooth passage of ureteric bougie indicates that the ureter is free, no surgeon would suggest exploration of this canal, but would direct his attention to the renal pelvis.

But there are certain conditions in which the operative technique is not established, and in which, I submit, the X ray is helpful.

(1) With recent symptoms of renal colic, if a small oval

calculus is shown by a shadow to be present in a ureter which is known by the history to have been dilated previously by the descent of calculi, then the case may be treated expectantly, for the stone may pass naturally.

(2) If a shadow shows a calculus to be just within the grasp of the vesical wall the surgeon may perform ureteric meatotomy through a supra-pubic incision in the male or through a Kelly tube in the female, and allow the stone to pass naturally.

(3) If the ureteric stone is long and thin and phosphatic, and is obviously travelling, then its descent and expulsion can be assisted and hastened by ureteric dilatation from the bladder (without cutting).

Let me explain these three positions more fully.

First Statement.

With recent symptoms of renal colic, if a small, oval calculus is shown to be present (radiographically) in the lower ureter, and there is a history of calculi having been passed previously, the case may be treated expectantly, especially if there be uratic or phosphatic urine present.

Cystoscopy shows that after a stone has passed the vesical orifice of the ureter that orifice is always dilated and dilatable. Clinically, it is admitted that in patients who habitually pass renal stones the later attacks are not nearly so painful or so long in duration as the earlier, and that this diminution of suffering is due to dilatation of the ureter, for as years go by the stones may be larger, and yet they are passed more easily.

Uratic and phosphatic stones pass more readily and with less pain than oxalates. Hence the discovery of a *small* stone in the lower ureter by radiography in a patient who has only lately suffered from stone symptoms should always be balanced by the past clinical history and the present condition of the urine.

I hardly think the above proposition will meet with disapproval. I hold, however, the same rule should

obtain with oxalate of lime stones, although these descend the ureter very slowly.

Even if the urine contain oxalate of lime, and the patient has had previous attacks after which stones were passed, it is quite allowable to wait and see what can be effected therapeutically.

PLATE XXXVII.

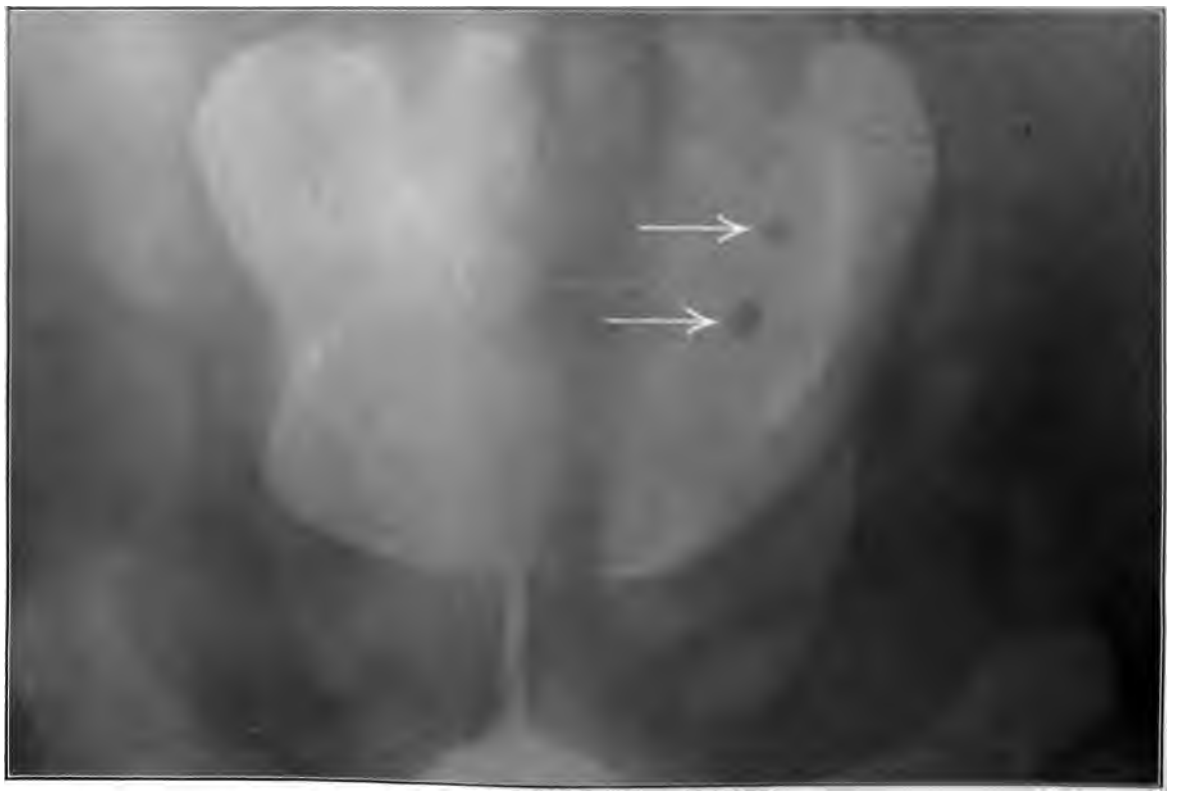

Shadow of two small oxalate stones (white-arrowed) descending the ureter.

PLATE XXXVII.

Illustration 1.—A. G—, aged 46, was sent to me, February 12th, 1907, by Dr. Harper, of Finchley, with the history that four weeks prior to his seeing me he had had a severe attack of right renal colic, which had recurred frequently during the first six days. I ascertained, however, that seventeen years ago the patient had had similar attacks on the right side during an entire year, resulting in the passage of a stone. It was probable, therefore, that the right ureter would be quickly dilated by a descending stone.

Cystoscopically the right ureteric orifice was patulous and thick.

Plate XXXVII showed two small oxalate of lime stones (white-arrowed) descending the right ureter of the bony pelvis area.

Acting on the above clinical knowledge I advised waiting in the expectation that the stones seen in the radiograph would pass.

March 20th.—Cessation of discomfort in ureter.

March 22nd.—Stones impacted in prostatic urethra. I pushed them back into bladder, crushed them, and sucked out the fragments.

April 6th.—Radiographed again. Pelvic ureter quite clear.

PLATE XXXVIII.

Illustration 2.—A. C—, aged 21 ; history of two years pain in right kidney and occasional hæmaturia on exercise.

Small oxalate of lime stone in pelvic ureter seen in radiograph (white-arrowed) negative taken November 23rd, 1904 (Plate XXXVIII).

It passed into bladder, from which I evacuated it February 2nd, 1905.

Rule 19.—Whenever a radiograph discloses a SMALL descending ureteric stone, it is advisable to ascertain if previous attacks were followed by the expulsion of stones; a habit of passing renal stones should weigh against ureteric lithotomy being early resorted to.

PLATE XXXVIII.

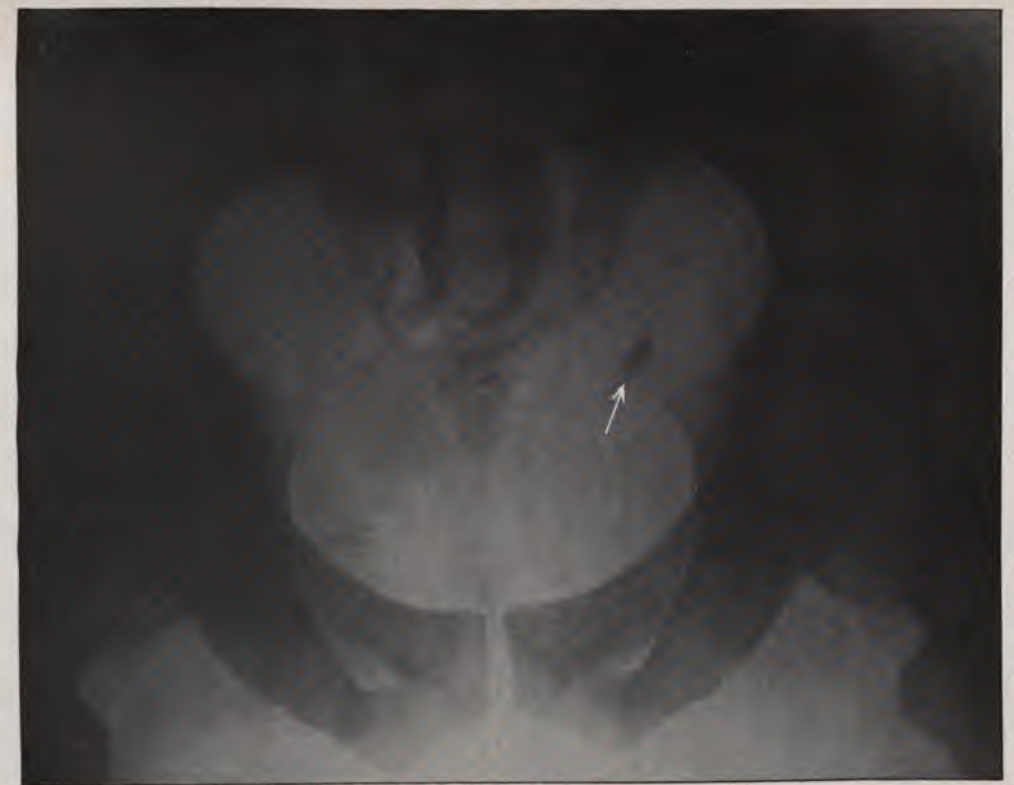

Shadow of an oxalate stone (white-arrowed) descending ureter.

Bale & Danielsson, Ltd.

PLATE XXXIX.

Shadow of oxalate stone (white-arrowed) traversing bladder orifice of ureter.

Illustration 3.—A transversely-placed elongated stone in left lower ureter entering the bladder.

Dr. Frank Hinde, of Sawbridgeworth, Herts, sent me a clerk, aged 25, with the following history. A year prior to seeing me he had frequent attacks of pain in the left kidney. They were most severe and left him with a dull pain after each paroxysm. Oxalates were present in the urine. He had been out of his employment for months owing to his bad health, and had just obtained a new situation when the attacks recurred with redoubled violence.

He was radiographed by Mr. Harnack, and the stone discovered in the lower ureter entering the bladder, in July, 1906 (Plate XXXIX).

This patient ought to have ureteric meatotomy so as to save the back pressure effects on the kidney, but the pain disappeared, and it was not till April 6th, 1907, that he had another attack, which lasted some days and culminated in his passing the stone. We can therefore formulate a second statement.

Second Statement.

If a calculus is just within the grasp of the vesical wall and is fixed there unduly the surgeon may perform ureteric meatotomy through the supra-pubic incision if the patient be a male, and squeeze the stone through. There are some stones which almost enter the bladder and yet stick at the ureteric meatus or just behind it in the channel of the ureter as it traverses the vesical wall and the kidney suffers greatly by its obstructing presence here. It is wiser to free the channel surgically than allow the renal tissue to deteriorate. Just how the surgeon may elect to do this is a moot question, though it should always be remembered that the dilated ureter and renal pelvis readily inflames and the renal tissues as readily participate. Above all things, therefore, roughness has to be avoided and subsequently drainage favoured.

In women, by use of the ureterotome, which is passed through a Kelly urethral speculum, it is easy to divide the ureteric mouth (meatotomy), and the stone will either come through with a little *abdominal* pressure[1] or rectal pressure, or it will pass naturally in a day or two. In the male I have utilised the same method as have many other surgeons, doing meatotomy through a supra-pubic cystotomy, but only when I have seen cystoscopically that there is no chance of a speedy delivery of the impacted stone.

Rule 20.—Ureteric meatotomy should only be adopted when a small transversely-placed ureteric shadow is proved radiographically and cystoscopically to be a stone within the grasp of the bladder end of the ureter and unable to pass the orifice.

Third Statement.

If the ureteric stone shadow is an elongated oval, and the urine be phosphatic, the descent of the stone and its natural expulsion may be assisted by ureteric dilatation (*per vias naturales*).

Some surgical knowledge, dexterity, and delicacy of touch are presupposed in this statement. The usefulness of the suggestion is, of course, restricted, but the manœuvre can be adopted with advantage in operative surgery, for such stones can be pushed up from below until they can be cut onto in the loin.

A few prefatory remarks on ureteric stone are necessary for the sake of clearness.

The *rôle* of the descending stone is not, I think, sufficiently realised by the profession at large. It is generally believed that once a calculus has entered the ureter it is "coming down all the while," and that after a brief stay in the ureteric canal it will drop eventually into the bladder, also that only occasionally it gets "hung up" in the ureter at a narrowing. Now the X ray and operative

[1] Don't use vaginal pressure, for it is more difficult to apply; a finger on the ureter *per vaginam* sometimes drives the stone up the ureter and not down.

interference teaches that this view is hardly correct. The difficult descent of a renal calculus along the ureter depends not so much upon the narrowings of the channel as upon the power which the stone possesses of irritating the mucous membrane, so as to produce local swelling and local reflex spasm. Given a stone like a smooth uratic calculus and a normal ureter, a transit of short duration can be anticipated once the calculus is fairly under way, for smooth uratic stones do not irritate. On the contrary, if the surface of the stone be acicular and extremely irritating, as obtains in the oxalate of lime class, the transit may be very tedious, lasting years, because great swelling of the mucous and sub-mucous tissues is always induced. Moreover, the stone partially sinks into the swollen surface, and is often fixed by spastic narrowing of the tube.

It would occur to a casual observer that it would be easy enough to pass a bougie from above and drive any lingering or impacted stone on into the bladder. But this cannot be done with safety to the integrity of the tube when the stone is an embedded oxalate, for the tube is much softened and lacerable, and may tear right across. With a smooth uratic stone a *vis a tergo* is generally unnecessary.

With the lime phosphate stone, however, it is feasible, because the stone is often long and narrow in shape and smoothish on its surface, and the ureter is not much swollen at the site of the stone. This manœuvre can be imitated by passing a bougie from below. Dislodgment of the stone and dilatation of the ureteric tube *below* the stone helps it to escape.

When the bougie is passed the hand can detect at once as to whether the stone can be shifted or whether the stone is impacted by peri-ureteritis.

Plate XL shows a long, fish-shaped phosphatic stone in the left ureter of a gentleman whose case I utilise to illustrate the value of passing a dilating bougie up the ureter from the bladder through a ureter-cystoscope.

PLATE XL.

Illustration.—A gentleman, aged 33, was sent to me by Dr. Halstead Dixon with phosphatic cysto-pyelitis of the left side. This had developed after a severe attack of typhoid, in the course of which he was delirious for five weeks, and needed catheterisation.

When I saw him he had symptoms of descending calculus on the left side. His urine contained a very little pus—a mere trace of blood, much triple phosphate, numerous coliform bacilli, which gave the typical reaction of the *B. coli communis.* The specific gravity was 1012.

Mr. A. D. Reid, May 11th, 1906, X-rayed the patient for me, and produced the beautiful radiogram shown in Plate XL.

In this a fish-shaped stone shadow will be seen in the left ureter low down in the pelvis. The patient suffered severely.

PLATE XL.

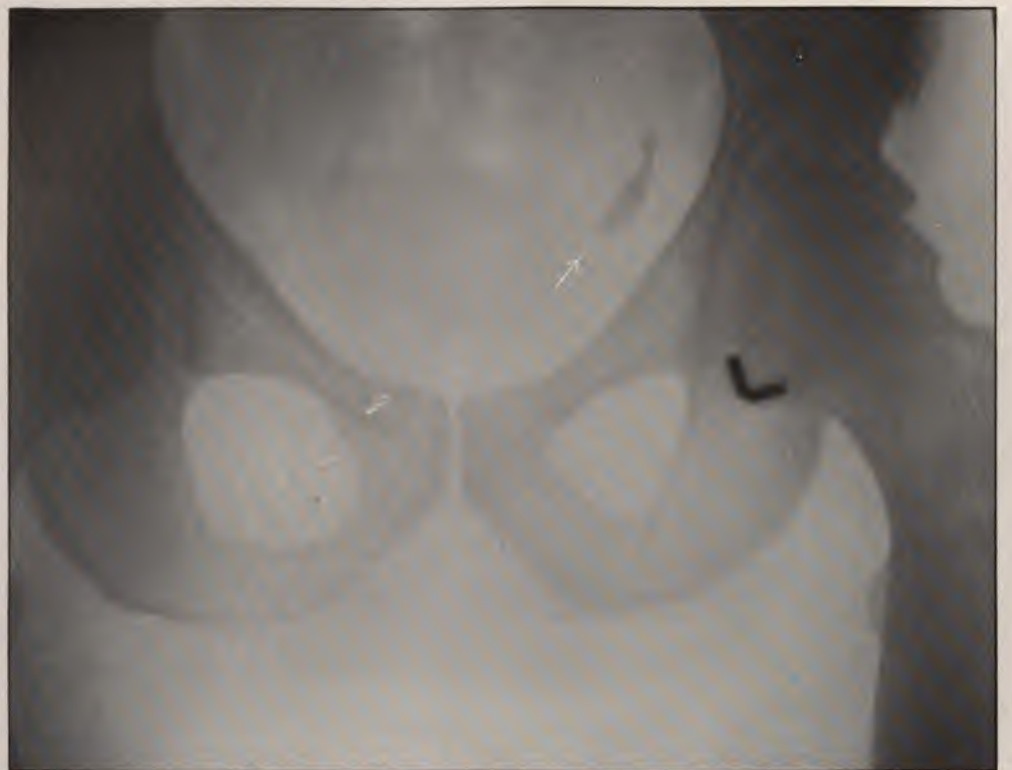

Shadow of phosphatic stone (white-arrowed) in ureter. (Mr. A. Reid.)

PLATE XLI.

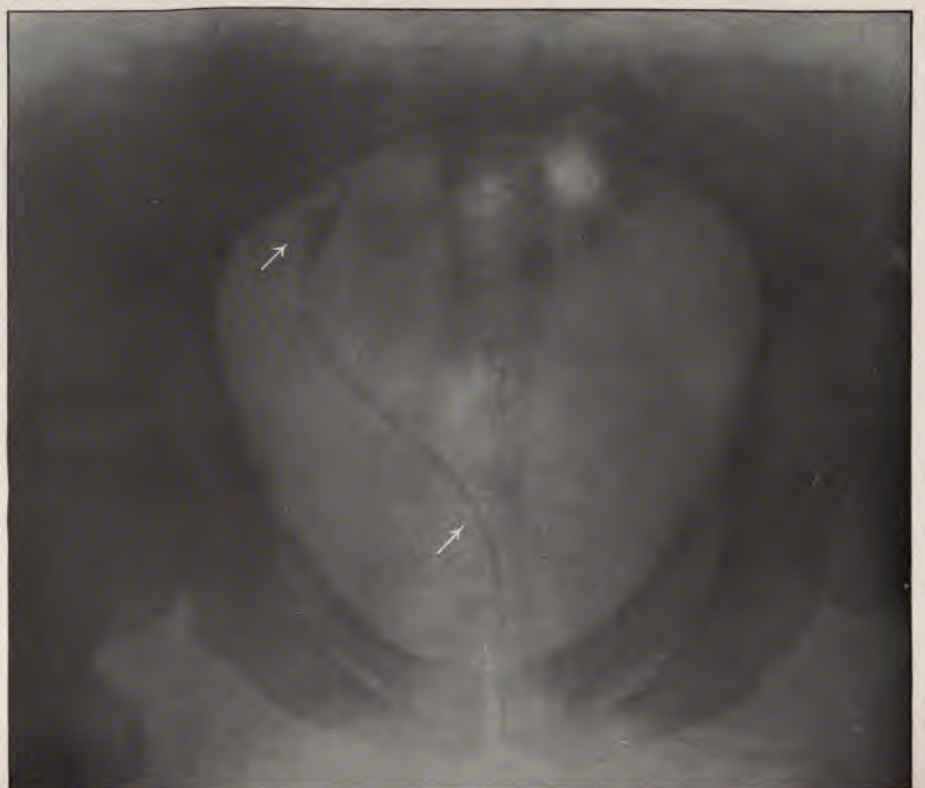

X-ray ureteric bougie (lower white arrow) dislodging ureteric stone (upper white arrow).

On May 21st, 1906, I passed a large ureteric shadowgraph bougie[1] through a Nitze catheter cystoscope and shifted the calculus higher and dilated the lower ureter. The result is shown in Plate XLI, which is a radiogram of same pelvis, taken by Mr. Harnack under an anæsthetic, May 21st, 1906. It shows the shadowgraph bougie (lower white arrow) pushing up stone (upper white arrow). The patient was now free from pain, and played

FIG. 5.—Stone passed by patient (actual size).

golf hard, and passed the stone (Fig. 5) easily *per urethram* seven weeks later.

I do not discuss or consider the *post hoc* or *propter hoc* success of this intervention. It gave me a very valuable idea, which I have utilised since in dealing with these cases.

[1] Made for me by Mr. Marshall, of Bell and Croydon, 50, Wigmore Street, London.

[2] This plate has not been artistically printed. For the sake of comparison with its fellow it should have been printed so that the side corresponded. The difference in the side is, however, merely a matter of printing.

CHAPTER VIII.

VISUAL FALLACIES IN THE RADIOGRAPHY OF URINARY STONE.

Up to this point only the positive, or the successful aspects of radiography have been presented to the reader. The negative side—the fallacies and failures—have now to be considered. This is undoubtedly the most important section of the work, and it is one upon which most personal labour has been bestowed.

As the radiographer became more expert, and the radiograms clearer in definition, there occasionally appeared upon the plates curious shadows which could not possibly have been cast by calculi. Many of these shadows were caused by faulty technique and plate defects, but even when the great improvement in all branches of the art had eliminated these obvious fallacies, certain fixed shadows were still encountered in the renal and ureteric areas which could not be explained otherwise than by regarding them as cast by calcareous glands or some other light-obstructing bodies. The knowledge of the true nature of these shadows was arrived at gradually, and at great cost, for operations were undertaken in the mistaken belief that calculi existed because of these shadows and no calculi were found. Such shadows may be termed false or mimetic shadows. A sound knowledge of their causation is not only essential for a radiographer, but of the highest importance to the operator upon whose judgment, knowledge and skill the success or failure of the intervention depends. Moreover, it is an interesting as well as a

valuable study to the clinician, for a correct appreciation of the nature of these false shadows may afford a clue to an otherwise unexplainable train of symptoms. I hope to be able to illustrate all these points.

The conditions which are mainly responsible for the appearance of fixed false shadows (mimetic shadows) upon the radiographic negative are, in their order of frequency :

(1) Phleboliths (calcareous infiltration of a thrombus).
(2) Lymphatic glands undergoing calcareous changes.
(3) Patches of atheroma in vessels.[1]
(4) Appendical or intestinal concretions.

(1) The Shadow Mimicry of Ureteric Stones by Phleboliths.

Phlebolith shadows are nearly always seen within the area of the bony pelvis. They are often so similar in appearance and in position to the shadows cast by small stones in the lower ureter, that they have been and are still a fruitful source of difficulty and doubt. I propose, therefore, to deal with them first, and to allude to their pathological, anatomical and clinical aspects somewhat fully, for these have not yet been accorded that attention in the literature which their importance deserves, or, in fact, demands.

I have not here, as elsewhere, failures in diagnosis and fruitless operative search of my own to record, for I used a ureteric guide, and later a shadowgraph bougie very early in my work, and was thus enabled to detect true ureteric stone and avoid mimetic shadows. But I never knew for certain what the small round false shadows were due to, until I obtained the assistance of our surgical registrar, Mr. F. S. Kidd, and Mr. Harnack, of the X-Ray Department. They worked together at my request upon thirty post-mortem subjects.

[1] I do not allude to calcareous walls of echinococcic cysts. They are too rare for consideration here.

Report by Mr. F. S. Kidd.

Method.—X-ray negatives were obtained from a series of suitable subjects in the post-mortem room. Whenever abnormal shadows appeared on the plate careful dissection of the pelvic contents was undertaken, in order to discover the cause of the shadow. Thirty subjects were photographed in all, eight of which showed abnormal shadows. The subjects were carefully selected, all those being rejected who were under twenty-five years of age, as it was considered unlikely that phleboliths or atheromatous plaques would be at all common below that age. It was also found necessary to use only those who were thin, and whose intestines were not too distended with gas. Even then the intestinal gas present was found to fog the negative very considerably, so that in the subsequent work of localisation of phlebolithic areas, the intestines were removed before the negative was taken.

In each case the subject was placed on the back, the plate between the sacrum and the table, the tube vertically over the umbilicus. This position was adopted so as to tally with that utilised in the wards.

Of the thirty subjects examined no less than eight presented concretions in the pelvis other than ureteric calculi; seven had phleboliths, one a calcareous plaque in the artery.[1] This proves how extremely common these concretions are, and shows how necessary it is for the surgeon to be acquainted with such shadows if he would not submit his patient to a fruitless search for a ureteric calculus.

None of these seven phlebolithic patients showed symptoms of ureteric calculus during life. Their average age was forty-seven, only two being under the age of forty-three. There were four males and three females, so that the condition is by no means confined to females, in whom the diagnosis and treatment of ureteric calculi is less difficult than in males.

[1] Referred to later, p. 100.

The Causes and Characters of the Shadows.

On seven occasions the shadows were cast by phleboliths. The phleboliths were all found in the plexus of veins which lies in the pelvic cellular tissue, running along the side walls of the bladder, uterus, and rectum, and near the spot where it passes beneath and behind the ureter to join the internal iliac vein by means of the inferior vesical trunk.

The characters of the phlebolith shadows were as follows:

Their size varied, but that of the largest measured 10 by 6 millimetres, that is to say, somewhat larger than the size of shadows cast by ureteric calculi large enough to become impacted. The size is therefore of little value in making a distinction.

Their shape was circular or slightly ovoid. The long axis of the ovoid was sometimes exactly in a line with the long axis of the ureter. If the shadow, therefore, is circular, it is a point in favour of phlebolith, but otherwise too much stress should not be laid upon the shape.

The outline was sharply defined in every case, and evenly rendered, in contrast to the less definite and often irregular edge of a calculous shadow.

The density of the shadow was very intense, that is to say, its image always stood out as a bright white spot in the black background of the surrounding parts of the negative. It was also quite homogeneous, being of the same intensity throughout. This is just what might be expected if the formation and structure of a phlebolith be remembered, namely, the deposit of calcium salts evenly throughout the concentric laminæ of a blood-clot; and is in contrast to the uneven shadow of many calculi, which consist of different salts that vary in their opacity to the X rays.

The position of the shadows was always very near the line of the ureter, corresponding somewhat to the position of the phleboliths found post mortem, which were all in

very close proximity to the vesical opening of the ureter. If two or more shadows were present, a line was drawn through the centres of adjacent shadows. In some cases this line corresponded to the long axis of the ureter, but in others it was clearly in some other axis, so that this point often proved of great use in attempting to infer the nature of the concretions casting a shadow.

Multiplicity of shadow, then, may help if some of the shadows are out of line of the long axis of the ureter.

To sum up, the chief points that should lead to a diagnosis of a phlebolith are: (1) A circular white spot on the plate; (2) a sharply cut rounded border; (3) bright homogeneous surface. The direction of the common axis of multiple shadows should often make the matter a certainty.

It must be noted that no instance of calcareous tuberculous glands was found in this series. It is often stated that their occurrence is common. This is incorrect. There are many clinical reasons for believing that such glands are not *common* in any position in the pelvis that is occupied by calculi and phleboliths. They are more likely to occur along the brim of the true pelvis, and along the transverse processes of the lumbar spines.

Reports of Cases.

Case 1.—Margaret M—, aged 50.

The *negative* shows a small *round* shadow, with well-defined margin, and even density, one inch below the ischial spine on the left side of the pelvis (Fig. 6).

Post-mortem findings. — Old phlebolith, round and smooth, and situated in obliterated vein of the left lateral uterine plexus; ureters empty.

Reflections.—Shadow is too definite in outline, too homogeneous, and perhaps too small for that of a ureteric stone. It is exactly in the line of the ureter. No symptoms of stone.

CASE 2.—Joseph S—, aged 49.

The *negative* shows two shadows in line of left ureter,

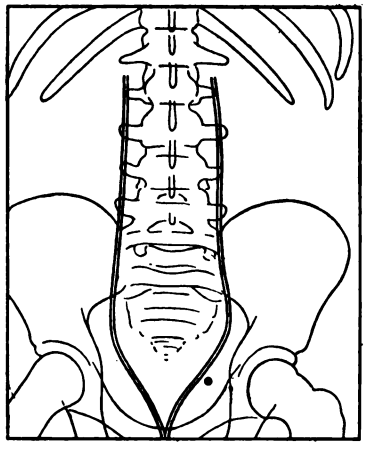

FIG. 6.

just below left ischial spine. Shadows have a well-defined outline, are distinct and homogeneous. They are circular.

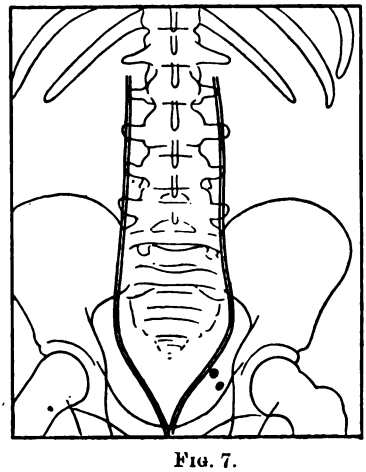

FIG. 7.

A line drawn through the centre of each shadow is not in the axis of the ureter (Fig. 7).

Post-mortem findings.—Two large phleboliths in the posterior part of the left lateral vesical plexus, just outside and behind the ureter, as it crosses the pelvic floor. Ureter empty.

Reflections.—The characters of the shadows, and the fact that they do not both lie in the axis of the ureter, should have sufficed in this case for a diagnosis. No symptoms of stone.

CASE 3.—Ellen I—, aged 47.

The *negative.*—Small ovoid shadow along the line

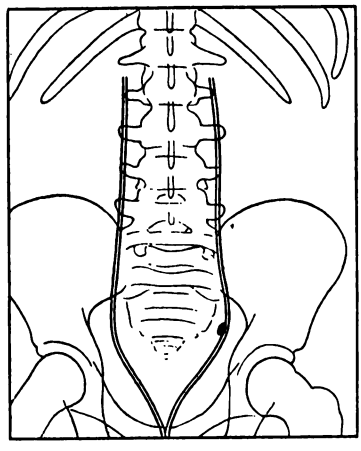

FIG. 8.

of left ureter, above the ischial spine; edge fairly well defined, homogeneous (Fig. 8).

Post-mortem findings.—One small phlebolith found in the veins of the left broad ligament, just behind the ureter, as it passses into the base of the broad ligament. Ureters empty.

Reflections.—No symptoms of stone. Characters of shadow in favour of phlebolith.

CASE 4.—Edward P—, aged 47.

The *negative.*—Two shadows on right side of pelvis, just inside the ischial spine. Round, well-defined edge, homo-

geneous, very clearly seen. A line drawn through the centre of each is not in the axis of the ureter (Fig. 9).

Post-mortem findings.—Two phleboliths in right lateral vesical plexus of veins, beneath and behind right ureter as it crosses the floor of the pelvis. Ureters empty.

Reflections.—No symptoms of stone. Character of shadow, and the fact that a line drawn through each is not in the axis of the ureter, are against stone in the ureter.

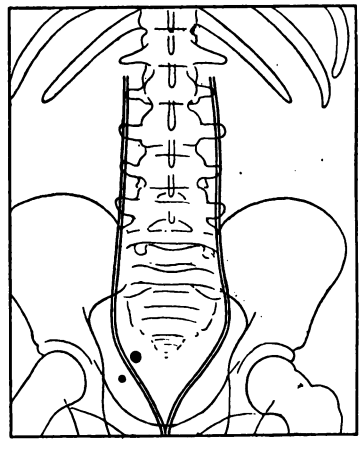

FIG. 9.

CASE 5.—Jennie S—, aged 29.

The *negative.*—In line of right ureter, above the ischial spine, is an ovoid shadow. Outline sharply defined, shadow homogeneous and very distinct, forming a bright white spot in the negative (Fig. 10).

Post-mortem findings.—One phlebolith in the right ureteric plexus of veins, behind and below the right ureter, as it crosses the pelvic floor. Ureters patent.

Reflections.—No symptoms of stone. The character of the shadow very much in favour of phlebolith in this case.

CASE 7.—Alfred A—, aged 28.

The *negative.*—Two shadows in line of left ureter, just inside the ischial spine. One round, and one ovoid well-

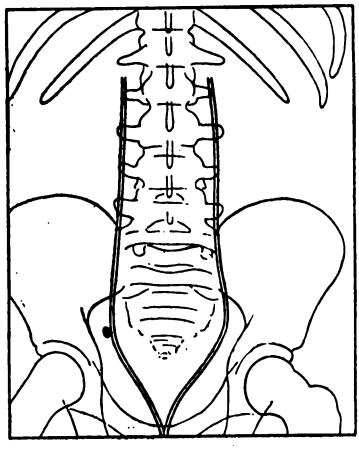

FIG. 10.

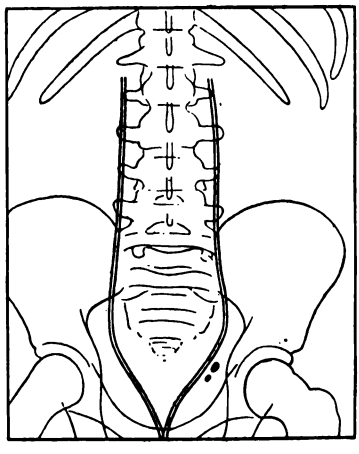

FIG. 11.

defined bright white spots on plate, homogeneous (Fig. 11).

Post-mortem findings.—Two phleboliths in left lateral

vesical plexus of veins, just below and behind left ureter. Ureters empty.

Reflections.—No symptoms of stone. Character of shadows points to phleboliths.

CASE 8.—William H—, aged 57.

The *negative.*—Four shadows along line of left ureter, but two are side by side and their common axis not in the long axis of the ureter. Two are very large, and measure

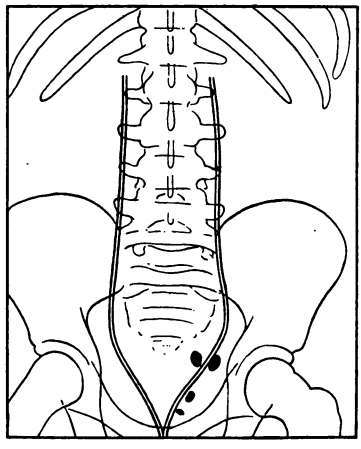

FIG. 12.

10 by 6 millimetres. Rounded, clearly defined margin, bright homogeneous white spots on the plate (Fig. 12).

Post-mortem findings.—Tuberculosis of prostate, bladder, left ureter and kidney. Four large phleboliths in left lateral vesical plexus of veins. Clots in the prostatic plexus, secondary to recent tuberculous prostatitis and cystitis. Ureters patent.

Reflections.—These shadows are larger than those of some impacted ureteric calculi, but these characters and the lines of their common axis make it certain that they are not ureteric calculi; and they are, moreover, too well defined for calcareous glands.

The Anatomical Findings of Phlebolithic Venous Areas.

Report by Self.

Seeing that the rough examination made by Mr. F. S. Kidd of the bodies in the post-mortem room showed that most of the phleboliths which cast shadows were found in the venous plexuses running along the side walls of the bladder, uterus and rectum, and considering that a more careful dissection of these plexuses was needed than could possibly be carried out in the routine of the post-mortem room, I have thought it wise, at the risk of appearing tedious, to add the detailed dissection, which I have personally carried out, of these venous plexuses of fifty bodies of all ages. By this means I hope to be able to demonstrate the cause of the phlebolithic change, its exact positions, and its frequency of occurrence.

Statement.

Phleboliths are most prone to form on the distal sides of valves in veins.

But the entire venous system of the bony pelvis is accurately valved. My researches in 1885[1] demonstrated that "All the many veins which converge from the buttocks, genitals and lower extremities to the pelvis, be it to the true or false divisions of that cavity, are valved at their entrance into it. These valves—and some of the veins have two, or even three sets—allow the venous blood to flow freely into the abdomen, but prevent its escape therefrom. The accuracy of closure and the constancy of position of these entrance valves is most striking."

But phleboliths are not found at these valves, but are noticeable only at those of the veins of the vesico-prostatic and vesico-uterine plexuses.

[1] Hurry Fenwick, "Venous System of the Bladder and its Surroundings," 'Journal of Anatomy and Physiology,' vol. xix, p. 320, 1885.

PLATE XLII.

Veins of the vesico-prostatic plexus in a boy, showing the venous drainage from the bladder, prostate, and peri-rectal tissues; all pass backwards (to the right) into the internal iliac.

Now valves are present in all parts of the vesico-prostatic plexus (the labyrinth of Santorini) from its commencement at the pubic arch to its termination in the internal iliac vein. Every tributary vein [1] entering the plexus is also valved at its entrance—and is often doubly-valved (Plate XLII).

The valves in this large venous highway have three groups of valves: Those which guard the entrance of the dorsal vein of penis, those which guard its efflux into the internal iliac, and a middle group.

It is the middle group of valves, I believe, which are most often affected by disease, and most prone to determine clot and phlebolith. I will now illustrate the two main causes of venous disturbance which lead to clot-blockage, and phlebolithic formation in this system.

(*a*) Sudden destruction of valves by sudden increase of venous pressure necessary to rapidly establish a collateral circulation.

(*b*) Gradual decrease in the vitality of the valves and the deposition of clot behind them distally, these clots subsequently hardening by calcareous deposit into phleboliths.

[1] The large dorsal vein of the penis which runs in the median groove of that organ is valved, often trebly so, in front of the subpubic ligament. After passing backwards beneath this structure it splits into two parts. Each half, dividing and subdividing, courses backwards along its corresponding side of the prostate. Here it forms, with veins from the prostate itself, the pubes, peri-rectal tissue, anus, ureter, and vesiculæ seminalis—the labyrinthus venosus of Santorini.

(*a*) *Sudden disappearance of valves by pressure.*—A casual glance at Plate XLIII will reveal the entire valve-system in the veins of the anterior two thirds of a young man's bladder (right side) to be valveless—only the valves at the posterior aspect remain.

The inference may be incorrect, but it is presumed that acute septicæmia starting from some focus of the left lobe of the prostate suddenly blocked the entire *left* vesico-prostatic plexus of this patient and threw the burden of the blood return on to the right side, placing its valves, by over-stretching, *hors de combat.*

The bladder was removed from a man, aged 32, who was admitted into the hospital one day, and died the next of acute septicæmic poisoning. No history could be obtained and no exact source of the poison was diagnosed.

I dissected the entire vesico-prostatic system after my usual method.[1]

The entire left vesico-prostatic plexus was plugged with clot; some of these were non-adherent, all were colourless, and the vessels were obviously contracted and thickened. The corresponding lobe of the prostate in this case seems to have been torn up by a catheter. There was, moreover, considerable amount of inflammatory matting of the tissues in this region and a slight layer of lymph on the peritoneum of the posterior surface of the bladder on this side.

Clinically, I need hardly emphasise the hazard of these clots, which form so readily in the vesico prostatic and renal veins and cause the heavy mortality of pulmonary embolism which obtains, though it is not recorded in the text-book literature of urinary surgery.

[1] One small track of a vein is dissected out at a time. Each end of the exposed piece is lightly clamped and injected with water slightly tinged with Berlin blue. This throws the valve into relief. The vein is incised over the valve to make sure of its existence, and it is then marked on the drawing. Each vesico-prostatic system occupied from two to three hours in dissection and depiction.

PLATE XLIII.

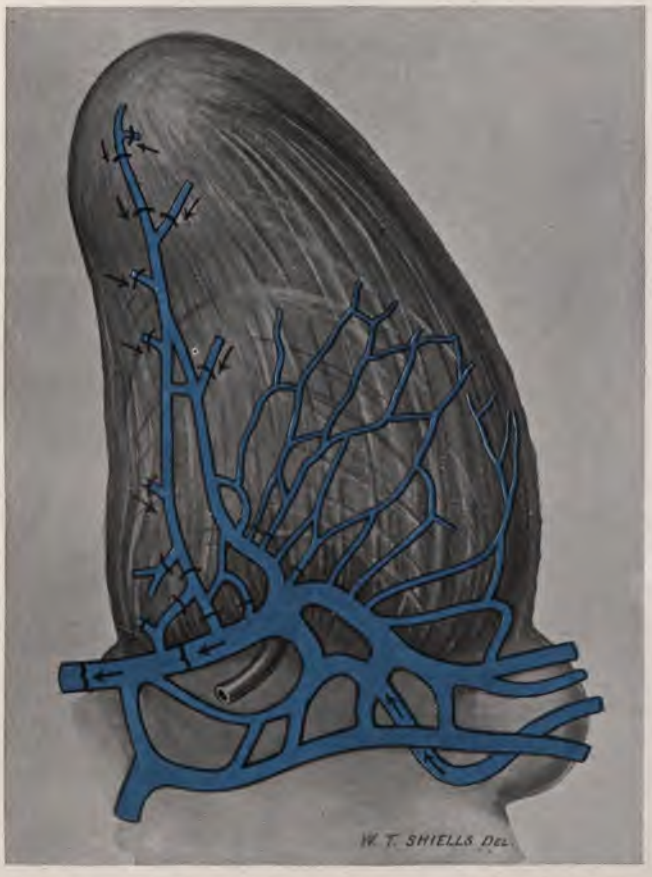

Vesico-prostatic plexus of a young man (prostate to the right). Entire valve system in anterior two thirds of the plexus destroyed presumably by sudden pressure.

PLATE XLIV.

A. Centre of Venous Disturbances.

Vesico-prostatic plexus of an adult, showing obliteration of veins and formation of phleboliths (white shadings).

(*b*) *Slow formation of phleboliths in the vesico-prostatic plexus.*—The gradual formation of phleboliths after obliteration of the venous channels is well shown in Plate XLIV.

This bladder was removed from a man, aged 37, who died of advanced arterial disease. Both right and left vesico-prostatic plexuses were affected, but the right more so. It will be noticed that the middle area of the plexus is most affected, that many of the valves are destroyed, that phleboliths are forming on the distal side of valves.

It might be asked how often may we expect to encounter phlebolith markings in radiographs of the pelvic area. My own statistics (22 per cent.)[1] do not help materially, for they are taken from the dead house, and do not accord with my experience of the routine radiography of the living.

Phlebolith markings in the pelvic area are of *frequent* occurrence in cases with *renal* pain. This fact contains, I believe, a clue to some of the unrecognised causes of obscure reno-ureteric pain.

There does not seem to be any correspondence between systemic disease, unless it be atheroma, and phlebolithic change (*vide* list in appendix), but there is no doubt in my mind that the varied inflammatory processes incidental to disease of the sexual organs in both sexes influences very materially the production of phlebolithic concretions.

[1] Age.	Healthy vesico-prostatic venous plexus.	Destroyed or impaired vesico-prostatic venous plexus.	Phleboliths in vesico-prostatic venous plexus.	Rough proportion of phlebolithic cases.
Fœtus and up to 10 years	9 cases	—	—	—
11–20 years .	5 „	1 case	1 case	$\frac{1}{6}$.
25–28 „ .	1 case	3 cases	2 cases	$\frac{1}{2}$.
30–39 „ .	5 cases	8 „	2 „	$\frac{1}{6}$.
40–49 „ .	3 „	5 „	3 „	$\frac{1}{4}$.
50–82 „ .	1 case	8 „	3 „	$\frac{1}{3}$.

The usual Radiographic Positions of Phlebolith Shadows.

Phlebolith shadows are almost always seen upon the plate within the shadow area of the bony pelvis. As the shadows are cast by phleboliths in the veins at the base of the bladder, it might be thought that they would only appear low down near the margin of the pubes and would not approach the line of the ureter high up in the bony pelvis. A moment's reflection will correct this view (*cf.* page 55 (*c*)). The light strikes obliquely downwards on to the plate, and the shadow cast by the ureter, as determined by a radiographic bougie lying in its channel, though on a higher plane, may coalesce with a shadow of a phlebolith situated on a lower plane.

A practical illustration is supplied in Plate XLV.

A radiographic bougie was laid in the right ureter, and a ring of silver wire was placed over the right vesico-prostatic plexus. The body was then X-rayed. It will be seen how the shadow thrown by the wire appears as if it lay in the ureter high up in the pelvic cavity. This parallax depends on the position of the lamp.

PLATE XLV.

X-ray ureteric bougie placed in right ureter. A silver ring (black-arrowed) placed over right vesico-prostatic plexus. Shadow of ring (black-arrowed) shows high up in pelvic area.

PLATE XLVI.

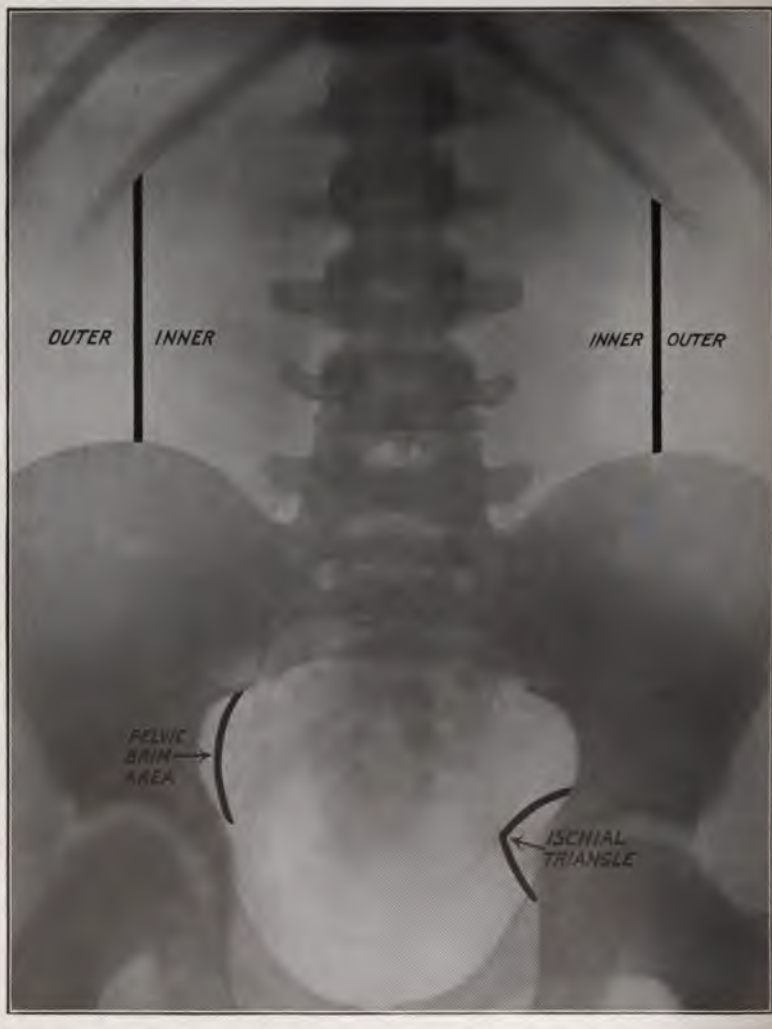

Radiographic diagram to show ischial triangle as a frequent site for phlebolith shadows, and the pelvic brim area for calcified gland shadow.

Practically, however, it rarely happens that a phlebolith shadow overlays the line of the ureter if the light is centrally placed; indeed, in most of the cases I have had the shadow or shadows lay near the ischial spine, so much so that I have been accustomed to call this area "the ischial triangle" (Plate XLVI), and to regard it as indicative of phleboliths affecting the corresponding vesico-prostatic or vesicular plexus or ovarian plexuses. In any case of doubt, where the shadow of a phlebolith coincides with the line of shadow of a ureteric bougie, a stereoscopic radiogram of the pelvis should be insisted on.

I have no reason for believing that the seminal concretions which were supposed to be frequently [1] met with in the seminal vesicles can or do throw shadows. More clinical evidence, however, will probably be forthcoming on this point.

Rule 21.—Do not casually diagnose a round, sharply-defined bright spot in the negative of a bony pelvis area to be a ureteric stone, even though it lie in the direct line of the ureter. Insist upon a stereoscopic radiogram. If still doubtful pass a radiographic ureteric bougie (one impervious to X ray), and let the patient be stereoscopically [2] rayed again with the bougie in situ.

Rule 22.—Suspect multiple sharply-defined spots in the negative of a bony pelvis area, especially if they are grouped around the shadow of the ischial spine, to be phlebolithic shadows.

[1] Seminal calculi as distinct from seminal concretions are composed of 90 per cent. of phosphate and carbonate of lime. They are said to grow as large as a cherry-stone, and such, of course, should throw a shadow with the ray, but I have never met a case. Compare Casper, 'Text-book of Genito-Urinary Diseases,' p. 442.

[2] For the advantages of the ureteric radiographic bougie, see page 115.

A Selection from my Clinical Cases in which Phlebolith Shadows were Discovered.

Case 1.—Descending ureteric stone suspected; negatived by radiography of the ureters; phlebolith found.

S. H—, aged 42. In June, 1906, patient had pain in her right side for a fortnight, and then passed a stone. The urine subsequently became bloody for a day or two.

In October, 1906, similar symptoms appeared—pain in right side, relieved by rest, frequency of urination increased by movement, but no blood appeared in the urine after the attack. *The supposition was that another stone would be passed.*

Cystoscopy.—Bladder healthy. Both ureteric orifices large. A radiograph ureteric bougie was passed up each ureter (double white-arrowed, Plate XLVII). No tactile evidence of stone in the ureters was obtained by this means, but the right bougie was checked at the fourth lumbar vertebra. A radiograph was then taken with bougies in position. A phlebolith (white-arrowed, Plate XLVII) seen *outside* track of bougie on left side. Right kidney movable.

Diagnosis.—No ureteric stone, merely mobile kidney.

Operation.—Right lumbar incision (October 18th, 1906). Right kidney found greatly displaced downward towards pelvic brim; fatty capsule was very slack. Renal pelvis was slightly hollowed, cortex healthy, ureter healthy. Fixation of kidney was carried out with entire relief of symptoms.

PLATE XLVII.

Phlebolith shadow (upper white arrow) outside ureteric X-ray bougie which lie in each ureter (lower double white arrows).

PLATE XLVIII.

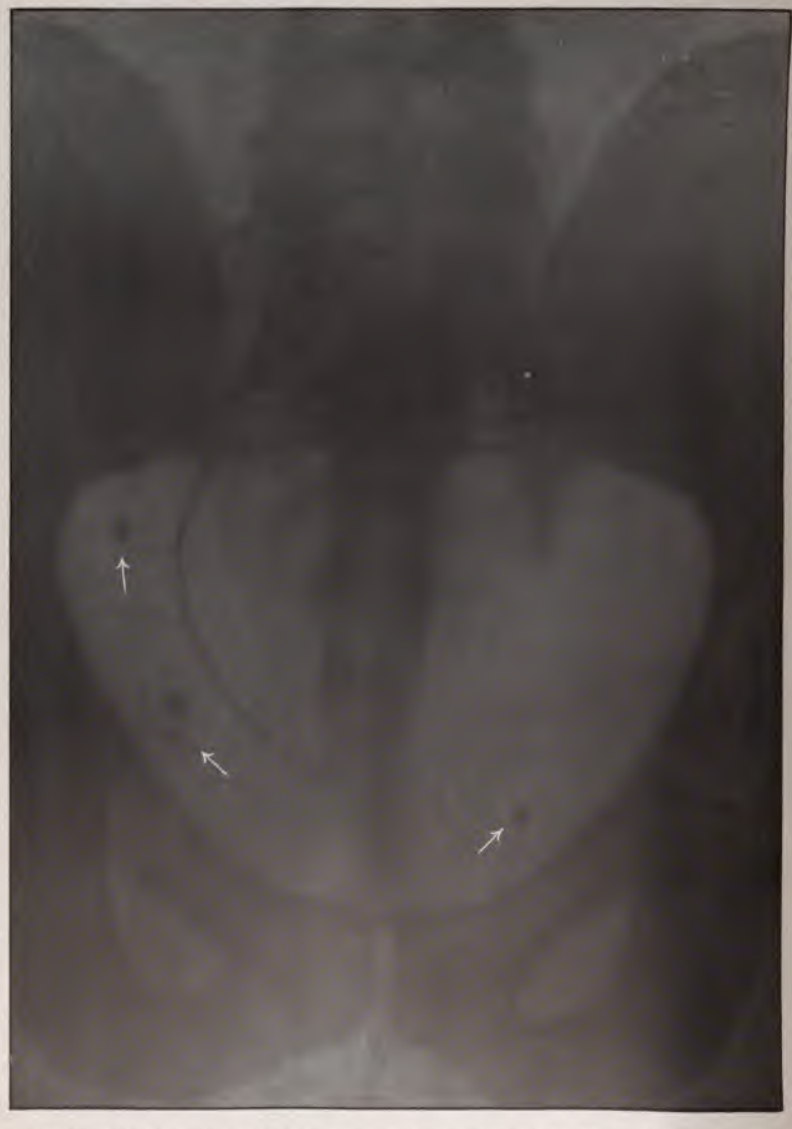

Shadows of phleboliths (white-arrowed) lie outside the track of left ureter. The dark curved line which crosses the left pelvic area is a shadowgraph bougie in the left ureter.

PLATE XLVIII.

CASE 2.—Descending ureteric stone suspected. Diagnosis negatived by radiography of ureter with X-ray bougie laid in it. Phleboliths found.

J. U. H—, aged 40. Had suffered eighteen years prior to admission from severe gonorrhœa, also syphilis. He was admitted complaining of pain in left loin and along left ureter, suggestive of descending stone. Radiographs showed shadows near left ureter. Bladder was shown to be healthy by means of the cystoscopy. A radiographic ureteric bougie was passed up left ureter (no stone felt in the channel), and a radiograph was taken whilst this was *in situ* (Plate XLVIII). Two phleboliths (white-arrowed) were seen outside the track of the left ureter, also another on the right side (white-arrowed).

Patient declared himself relieved of all symptoms by the intervention. Remained well.

PLATE XLIX.

CASE 3.—Agonising pain in perineum and anus was suffered by a patient who had been the subject of stone in the prostatic canal. Curiously symmetrical phlebolith shadows (white-arrowed) were seen in the obturator areas (Plate XLIX), the lamp being placed much lower than usual in order to define, if possible, a densely inflamed prostate and seminal vesicles, which I subsequently dissected out. The phleboliths had formed probably as the result of inflammation induced by a calculus, which had become lodged in the prostatic urethra for some years.

PLATE XLIX.

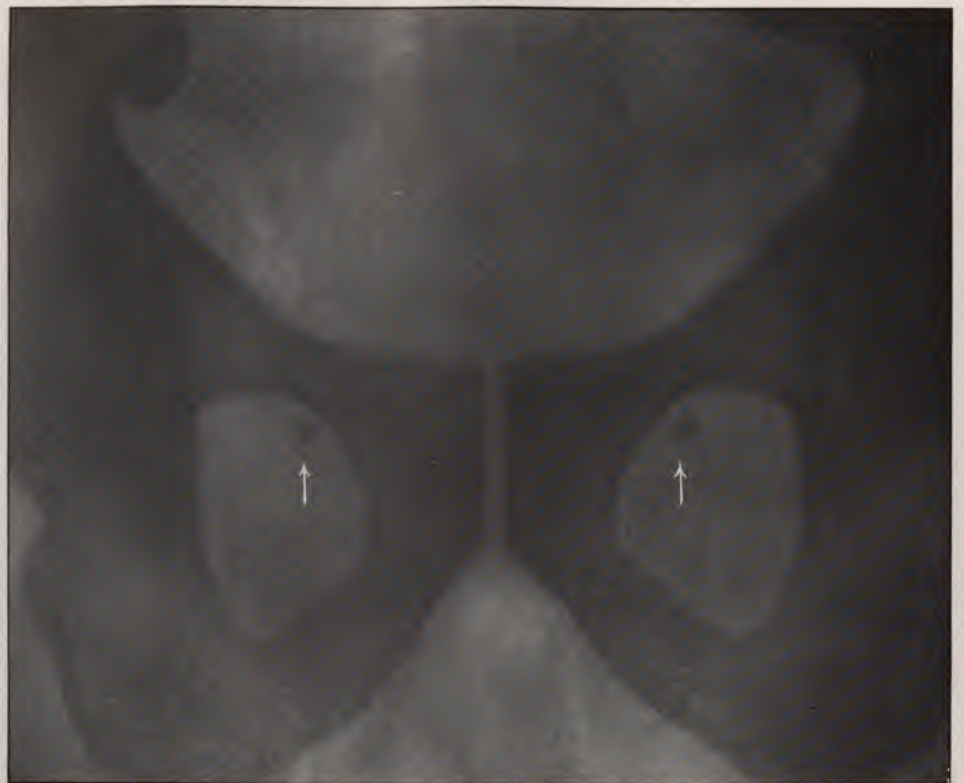

Bilateral shadows (white-arrowed) of phleboliths in vesico-prostatic plexus.
[The lamp was placed much lower than usual.]

PLATE L.

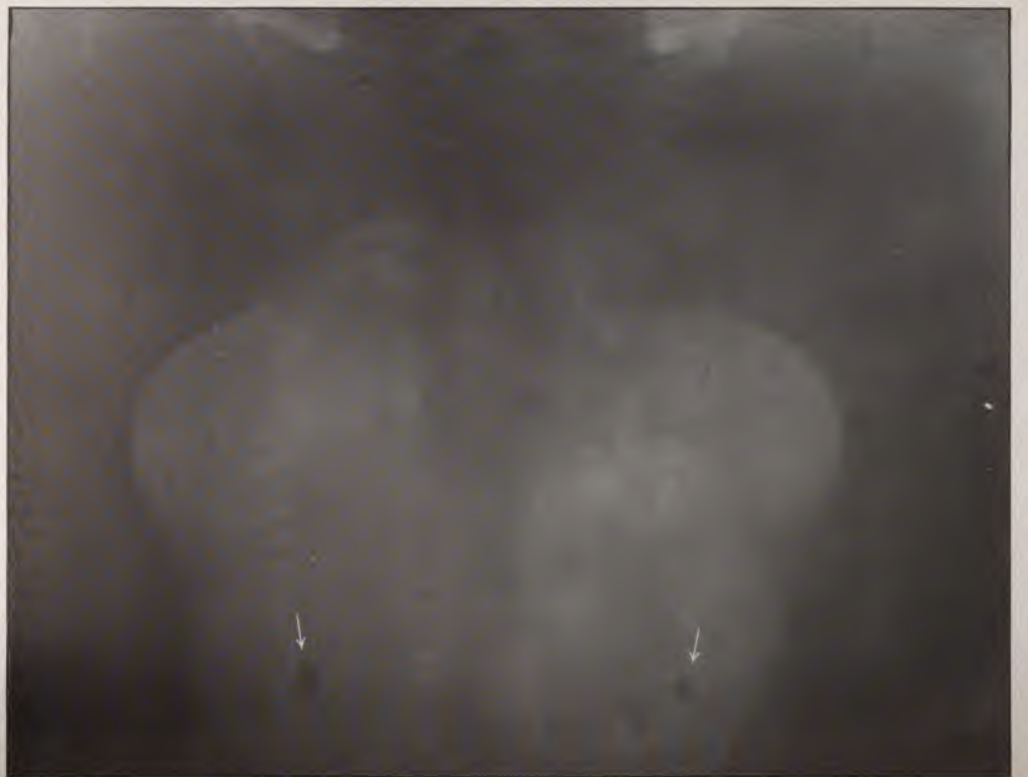

Bilateral shadows (white-arrowed) of phleboliths cast along the line of the ureters.

PLATE L.

Case 4.—Male patient, suspected to have descending calculi along both ureters. Curiously symmetrical phlebolithic shadows on both ureteric lines (white-arrowed) (Plate L). Both ureters patent.

J. H. H—, aged 32. A patient of Dr. Denning, of Elland.

Eleven years ago severe pain in right side at the appendix region; blood appeared in the urine. He has never felt this pain since.

Four years ago felt intermittent pain in the left loin at the costo-vertebral angle. Some days he is quite well and can walk twenty miles without discomfort. At other times the pain worries him in the left loin without any cause and extends all round the waist, but it is not severe. He is worse if he sits down.

Urine analysis.—No tubercle bacilli found, but urates and a few mucous threads containing pus cells and calcic oxalate crystals and a few blood discs. No casts or renal cells.

Final report after two years—well.

PLATE LI.

CASE 5.—Suspected stone in left kidney, phlebolith situated in left bony pelvis area (ischial triangle, Plate LI).

A. G. B.—, June 19th, 1905.

Sixteen years ago phthisis.

In 1892 congestion of the kidneys.

1900: Another attack accompanied by the passage of a fragment of stone.

April, 1905: Another attack of hæmaturia as the result of a chill—recurring—the urine being normal in the intervals. Mr. Lucy, of Plymouth, suspected stone in the left kidney.

The urine contained no tubercle bacillus.

Cystoscopy.—The ureteric orifice on the left side was a trifle red as if irritated by descending grit. The ureter was patent.

A phlebolith shadow was noticed at the left ischial triangle (white-arrowed, Plate LI).

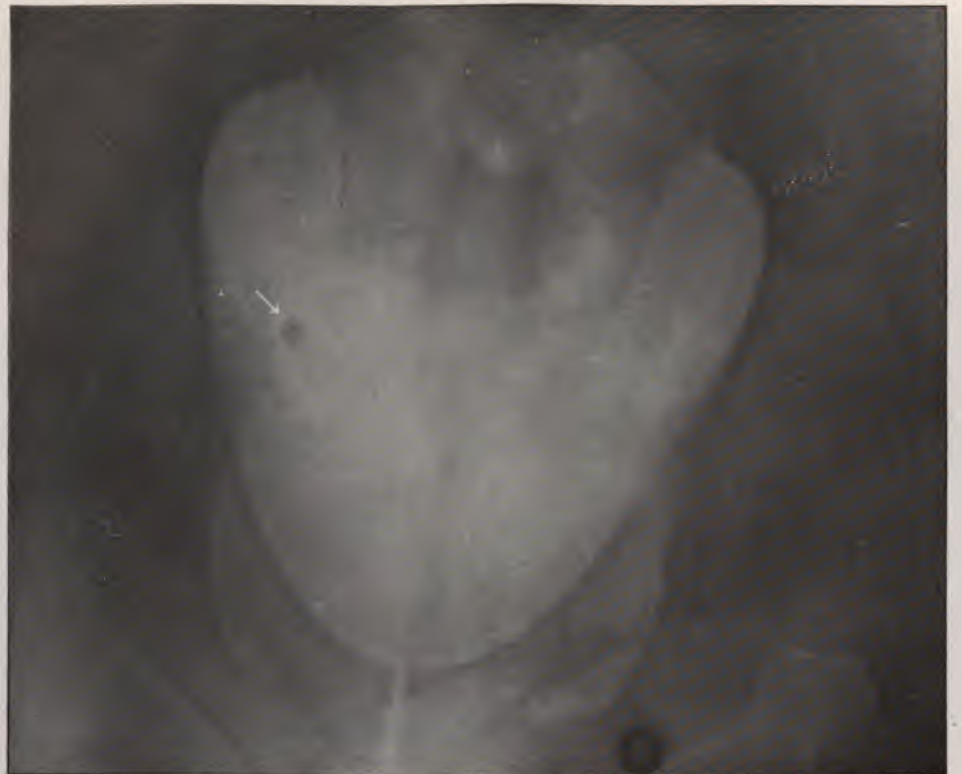

Shadow of phlebolith (white-arrowed) in left ischial triangle.

PLATE LII.

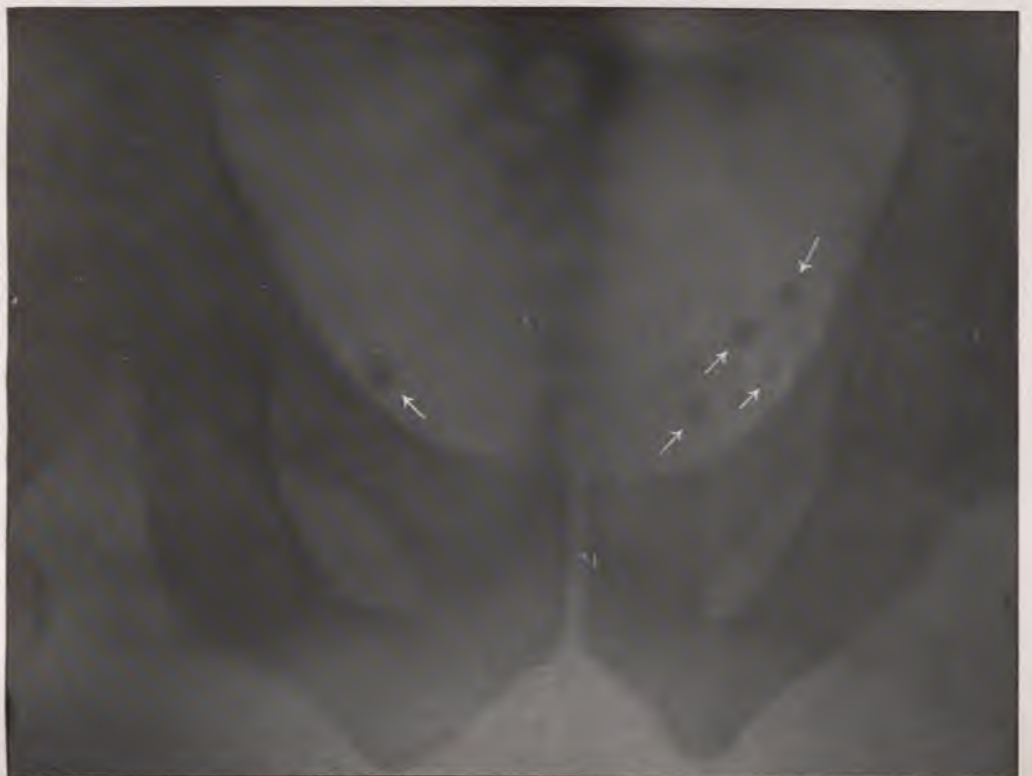

Shadows of phleboliths (white-arrowed) on both sides.

PLATE LII.

CASE 6.—Male; left renal stone suspected, radiograph showed phlebolith shadows on both sides.

Radiograph of a gentleman, aged 68, who was sent to me by Dr. Collier, with a history that 2½ years prior to his visit he had had an attack of left renal colic and passed blood in his urine. The pain was over in a few hours, and the blood ceased in a day or two. Five days prior to his visit he had another mild attack on the left side, followed by hæmaturia for a couple of days.

Between these two attacks the urine was always quite free of blood, pus or albumen, though at times uric acid crystals were freely deposited.

The X ray shows phlebolith markings on both sides of the pelvis area (white-arrowed, Plate LII). It will be noted that the shadows are scattered irregularly.

PLATE LIII.

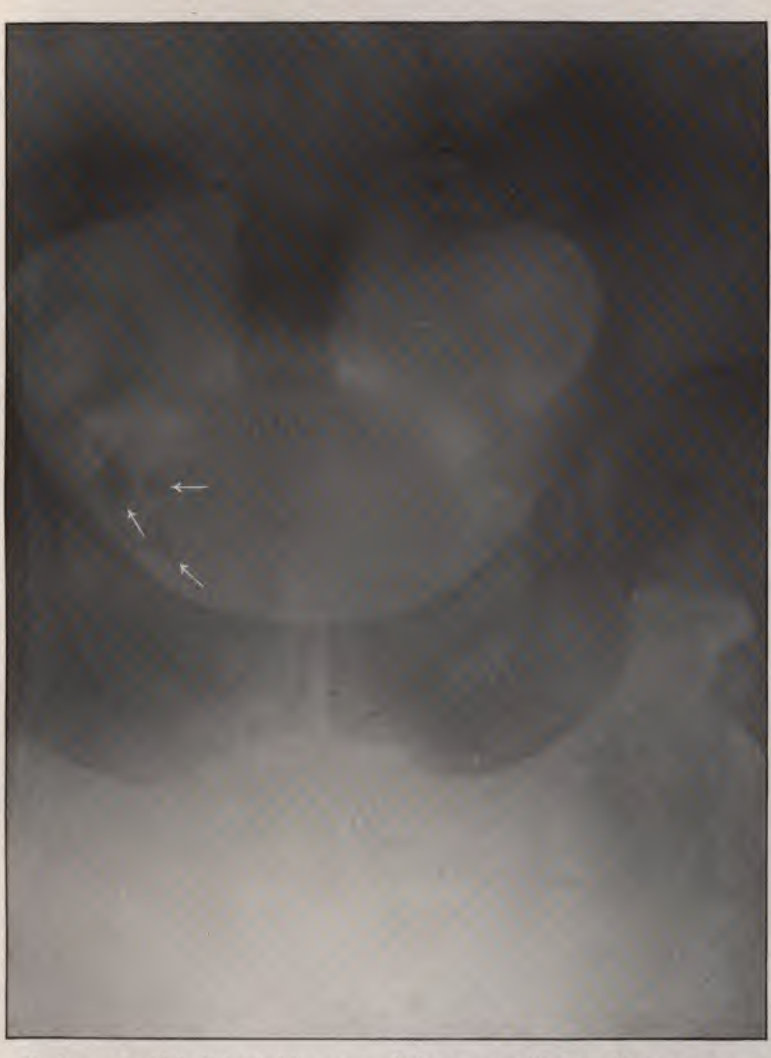

Shadows of phleboliths (white-arrowed) in a man with left-sided ascending tuberculous ureteritis.

PLATE LIV.

PLATE LIV.

CASE 8.—Phlebolith in left pelvic area (Plate LIV).

A lady, aged 30, with frequency of micturition, lasting four months, but without pain.

Cystoscopy showed the left ureteric orifice to be open, and the lips swollen. The right ureteric orifice was healthy. There was a prolapsed ovary on the right side. Ureteric bougie proved the ureter to be free.

Compare Mrs. S— for a similar appearance (page 102).

PLATE LIV.

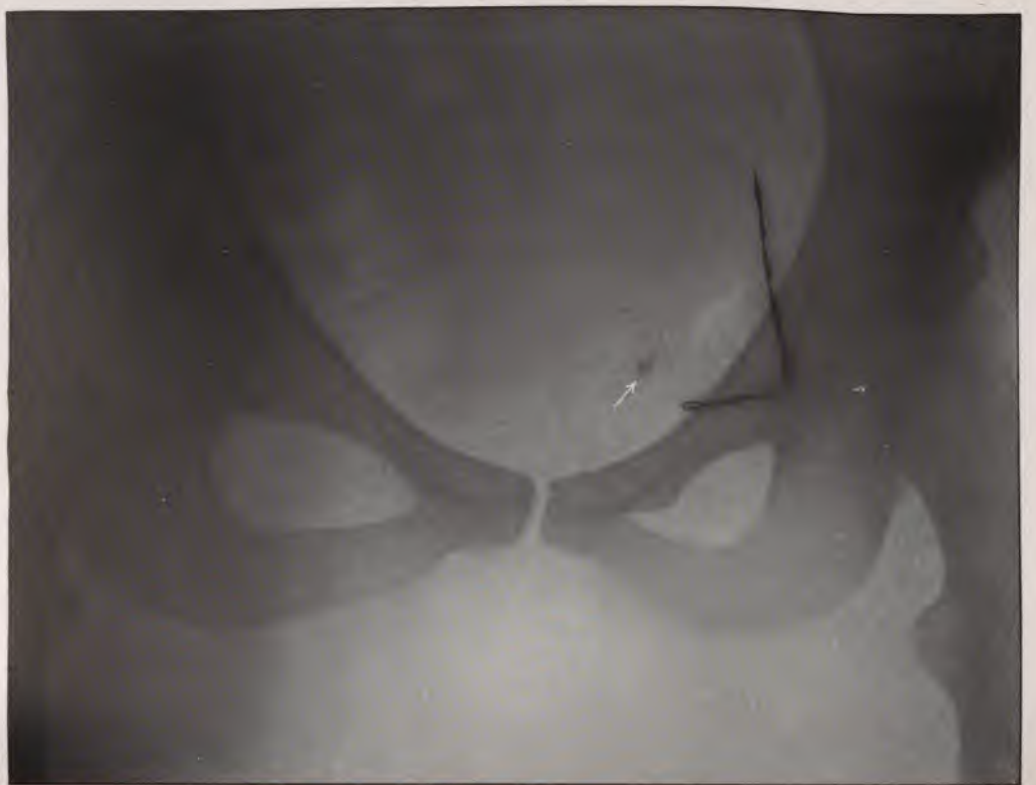

Single shadow of a phlebolith (white-arrowed). (Mackenzie Davidson.)

PLATE LV.

CASE 9.—Patient with suspected descending rena calculus; negatived; phlebolith markings in left pelvi area, white-arrowed (Plate LV).

Mr. L—, aged 46, sent me by Dr. Evelyn Taylor, o Scarborough, was perfectly well until Easter, 1892, whe he passed blood in his urine and had renal colic. He passe a lime oxalate stone in August, 1892. He was then fre and well for five years.

In 1897 was out bicycling when he was seized wit frightful pain in the rectum and penis. No difficulty wit urination. This pain has remained and is constant fo hours in the perineum. The prostate is thick and bigge than natural in a patient in the 40–50 decade. On the lef side of the pelvis in the radiograph were four phlebolit shadows (Plate LV). Bladder seen to be free by mean of the cystoscope.

Reported well two years later.

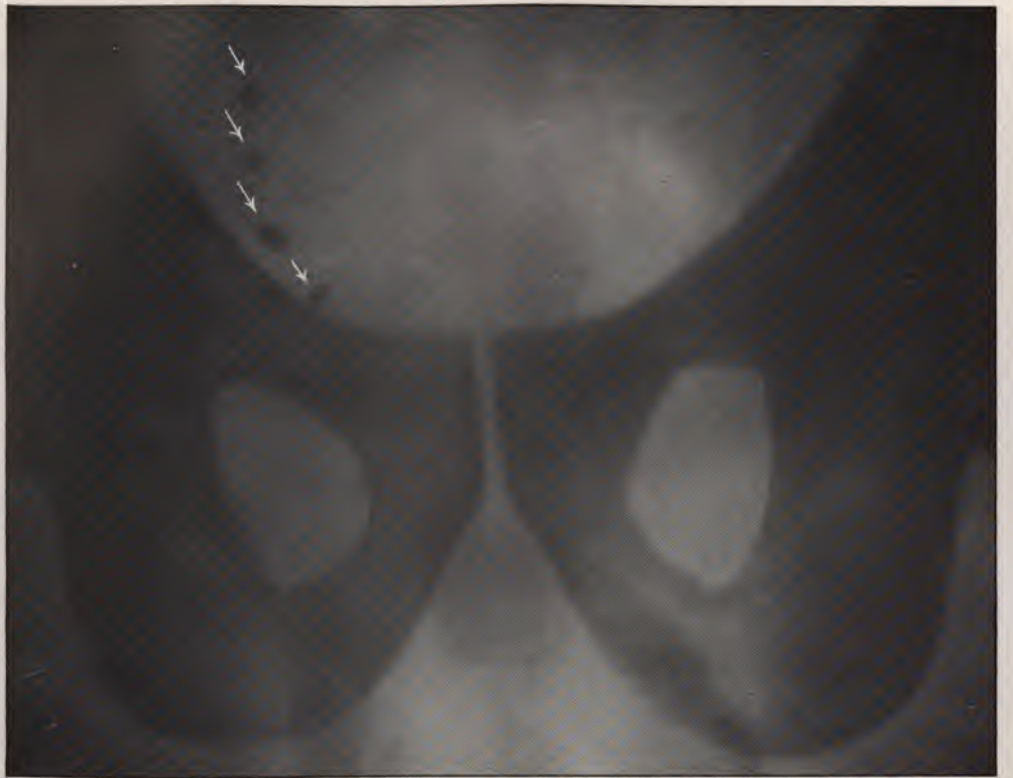

Shadows of four phleboliths (white arrowed) in left side of prostate.

PLATE LVI.

Phlebolith shadows (white-arrowed) in left side, the ureter being patent.

PLATE LVI.

CASE 10.—Shadows of phleboliths outside the left ureter (Plate LVI) of a young man who had repeated attacks of left oxaluric colic, and who had passed oxalate of lime calculi from the right side. The left ureter was proved to be free from stone by means of bougies passed through Nitze's ureter cytoscope.

CHAPTER IX.

VISUAL FALLACIES IN THE RADIOGRAPHY OF URINARY STONE—*continued.*

THE rarest group of visual fallacies, that which comprises the shadows cast by atheroma in vessels or by intestinal concretions, must now be considered, although it comes last in the order of frequency (*cf.* list, page 75). This arrangement will, however, simplify the text, for it will permit calcareous gland shadows to be alluded to just before the cognate subject of cretifying urinary tuberculosis.

3. THE SHADOW MIMICRY OF URINARY STONES BY ATHEROMATOUS PATCHES IN VESSELS.

I have but little clinical knowledge to record under this head. That patches of atheroma in the arteries do occasionally cast shadows both in the renal region and in the line of the lower ureter is well known, but the occurrence is apparently not common. The direction and position of the elongated shadow, for the shadow is usually elongated, is often sufficient to indicate its probable nature.

Mr. F. S. Kidd, our surgical registrar, examined such a case, which Mr. Harnack had radiographed, in the post-mortem room. He details its examination as follows:

"Male, aged 60.

"The negative of this body showed one large shadow

and several small shadows near it just below the line of the right sacro-iliac synchondrosis (Fig. 13). The edges are not well defined, and the shadow is composed of different densities. Moreover, the general axis of the shadows is not the same as the axis of the ureter.

"*Post-mortem findings.*—One large (half an inch long by one quarter wide) and several small calcareous plaques were found in the wall of an atheromatous right internal iliac artery. They existed in its lower portion, just where it turns forwards and outwards beneath the brim of the

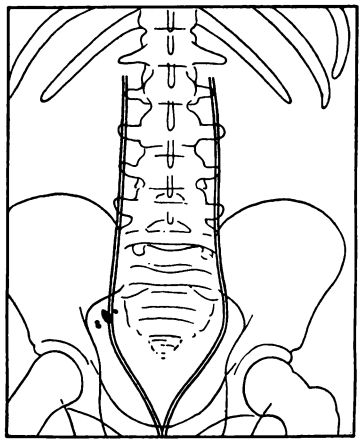

FIG. 13.

pelvis and gives off the gluteal, sciatic, and internal pudic arteries. The rectum was empty.

"*Reflections.*—The size and shape of this shadow would have done equally well for a ureteric calculus, as would also its outline and intensity, which latter varied just as in some calculous shadows. The long axis of the shadow, however, was almost at right angles to that of the ureter. This fact, and the absence of symptoms, would have distinguished it from that of a ureteric calculus. Enough has been said above (page 77) to show how different it was from the shadow of a phlebolith."

The only clinical example I can give of an atheromato patch casting a shadow is illustrated by the followi case and Plate LVII.

A small oval shadow, white-arrowed, supposed by t radiographer to be a right-sided ureteric stone is seen the pelvic area (Plate LVII). An X-ray bougie was pass along the ureter (Plate LVIII), and shows that the shado lay away from the ureter. Abdominal section: shado found to be caused by atheromatous patch in the rig internal iliac.

A lady, Mrs. S—, aged 40, was sent to me in Apri 1905, by Dr. Athel Saw, of Perth, W. Australia, wit pain in the *left* kidney. She had a history which point to intermittent hydronephrosis of the right kidney a cystitis, with ascending left-sided ureteritis and pyelo-nephritis. She had had right-sided nephropexy and le ovariotomy performed before she came under Dr. Ath Saw's treatment, but neither operation had relieved t pain in the left kidney.

I opened the abdomen in order to perform ventrifixati of the prolapsed uterus and thus had an opportunity thoroughly examining the pelvic viscera, and I detect the atheromatous patch in the vessel. I may say, ho ever, that prior to doing this I had passed a ureter X-ray bougie up the ureter and proved the shadow to cast by some body lying outside that canal and not by stone in that channel (Plate LVIII).

I can give no rule for the due recognition of the shado cast by atheromatous patches. The shadows are general irregular in outline and elongated, and when in the pelv area they are often placed at an angle with the line the ureter. I believe them to be rarely met with.

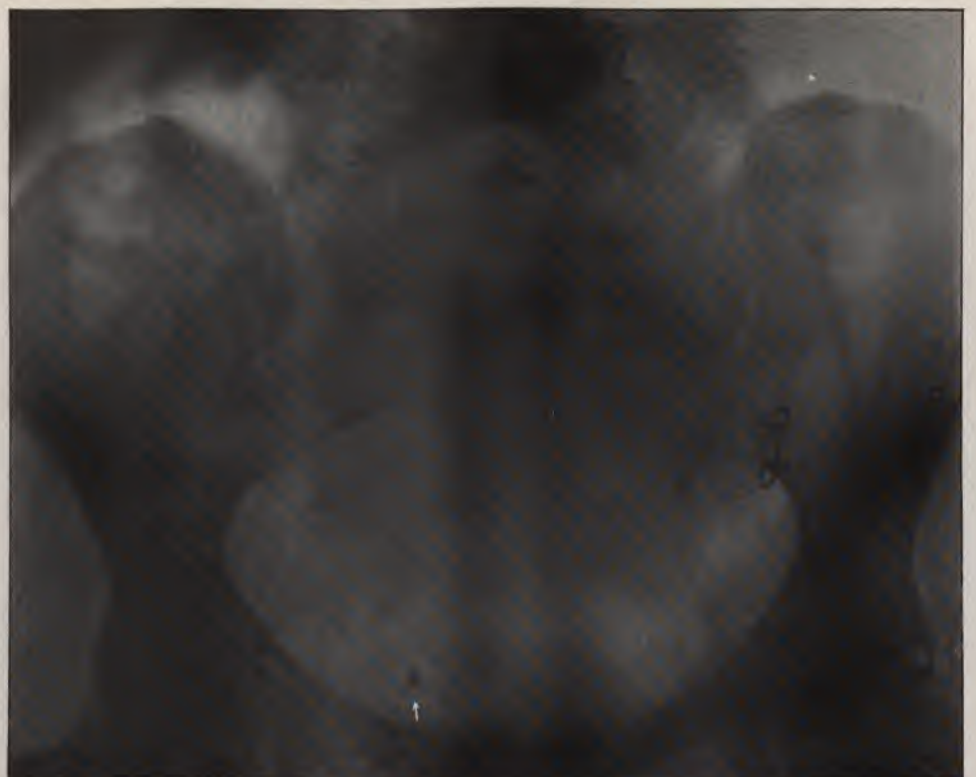

Bale & Danielsson, Ltd.

Shadow of an atheromatous patch (white-arrowed) in pelvic area.
(Radiographed by Mr. Mackenzie Davidson.)

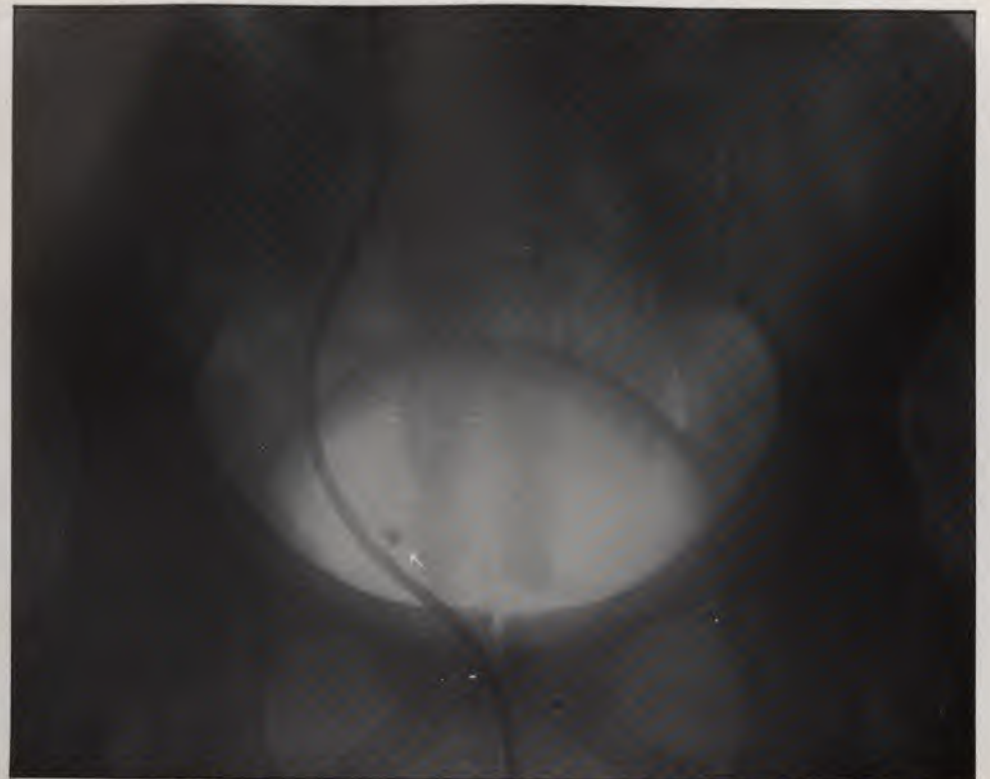

Same case as LVII. Ureteric X-ray bougie lying in right ureter. A shadow of an atheromatous patch (white-arrowed) shown to lie outside ureter. The pelvic area has been rendered light by air inflation of the bladder.

Bale & Danielsson, Ltd.

The Shadow Mimicry of Urinary Stones by Intestinal Contents.

It has been already mentioned (page 3) how easily fæces if coated with bismuth or phosphates may simulate stones in the urinary passages, but as these would be removed by the routine preliminary purge they would not occur in expert radiography, or if they did appear they would be at once recognised by the expert eye. I need not therefore enlarge upon the subject. Foreign bodies of a known or an unknown character which have been swallowed are purposely submitted to radiography and need not be alluded to, for shadows are expected and do not cause fallacy. Occasionally an ingested foreign body, of which the radiographer is unaware, may cause difficulty in recognition, but such shadows call for no comment. Certain fixed shadows, however, remain, and of these probably the most common and the most mimetic are cast by cretaceous fæcal deposits (fæcal concretions) in the appendix; one illustration will suffice.

Mr. D—, aged 43, was sent to me by Dr. Harris, of Croydon, in March, 1908.

The patient had had left renal pain and had passed dark urine at the age of 15.

Mr. Jacobson, of Guy's, had removed a stone from his left kidney when he was 25. During the eighteen years which have elapsed since the operation he has had pain not only in the left but also in the right kidney (posteriorly), and in addition he has had severe pain in the neighbourhood of the appendix. It was for the right-sided (posterior) pain that I was consulted.

He was X-rayed by Mr. Coldwell, and several stone shadows appeared in the radiograph in the left kidney.

But on the right side there was a shadow for which I could not account (Plate LIX).

To quote from my notes: "On the edge of the crest of the ilium on the mid ileo-costal line is an obliquely placed oval shadow. Mr. Coldwell suggests it is a button. Is it a ureteric stone? No; it is either a stone in a much dilated kidney pelvis (compare Plate XIII, illustration 4, page 18) or some adventitious substance in the bowel casting a shadow. But there is no distension of the kidney or its pelvis as evidenced by a bimanual examination of

FIG. 14.—A fæcal concretion.

the kidney region. This would eliminate stone in a greatly dilated pelvic bag.

"*Conclusion.*—I am uncertain what the shadow is."

Operation.—A small 1½ inch opening was made posteriorly on to right kidney. Pelvis and cortex examined by index finger. The organ proved quite healthy. No stone.

The incision was now increased downwards and the knife entered a zone of dense inflammatory material. A small abscess was suddenly opened and in it a fæcal stone

PLATE LIX.

(L.) (R.)

Upper shadow (black-arrowed) upon the iliac crest shadow is cast by a fæcal concretion in appendix. Small round shadow in pelvic area (black-arrowed) is a phlebolith.



was found (Fig. 14). On exploring further and carefully inspecting the hardened wall of the abscess sac a communication with it and the appendix (which lay alongside buried in inflammatory exudation) was demonstrated. The appendix was dissected out with the abscess sac wall.

Patient did well, losing the pain in the right side.

The Shadow Mimicry of Urinary Stone by Lymphatic Glands undergoing Calcareous Changes.

Every radiographer, except perhaps he whose material and experience are very limited, will have encountered shadows cast by packets of calcareous glands. Generally these shadows are characteristic both as regards position and appearance, but occasionally single glands with patchy calcareous changes in them appear in the hilus of the kidney or along the course of the ureter, and are apt, when in these positions, to cause much speculation as to their real nature. It rarely happens, however, that they imitate the shadow cast by urinary stone so closely that a false diagnosis of calculus is made and an operation is needlessly and fruitlessly carried out in consequence. But the mimicry is marked enough to be noticed here, for it may be dangerous to the inexpert.

It will be better to give first a few illustrations of shadows cast by calcified glands, of the nature of which there can be no doubt, and then subsequently to add one or two radiographs of cretified glands in which the mimicry of urinary stone is very marked.

A Contrast Radiograph—a Shadow of a Stone in the Kidney and of a Calcareous Gland.

I have met with no such brilliant contrast case as that which Mr. Thurstan Holland, of the Liverpool Royal Infirmary, has published,[1] and which I am permitted to reproduce:

"A young medical had a septic wound of the finger, and shortly afterwards developed a kidney abscess. This abscess was opened and drained, but the sinus showed no signs of closing, and on going most carefully into the history of the case it came out that, although for the past year he had been well, previously to that there had been attacks of very severe backache following exertion, and that this had continued for a considerable time. An X-ray examination showed the appearances seen in Plate LX, and at the operation a stone was removed from the kidney—the upper shadow (A)—and a fixed calcareous gland was found, which accounted for the lower shadow (B)."

Even a casual observer will be struck by the sharpness of the stone shadow and by the indefinite hazy periphery of the calcareous gland shadow, also by the characteristic *shape* of both shadows, the stone being triangular and the gland round. Most large glands are round. In most, also, if not in all my cases of large, more or less rounded shadows due to calcareous gland a misty outline is seen. I have usually found these large round glands situated in the mesentery of the bowel.

[1] "Some Difficulties in the X-ray Diagnosis of Renal Calculus," 'Archives of Röntgen Ray and Allied Phenomena,' August, 1907.

PLATE LX.

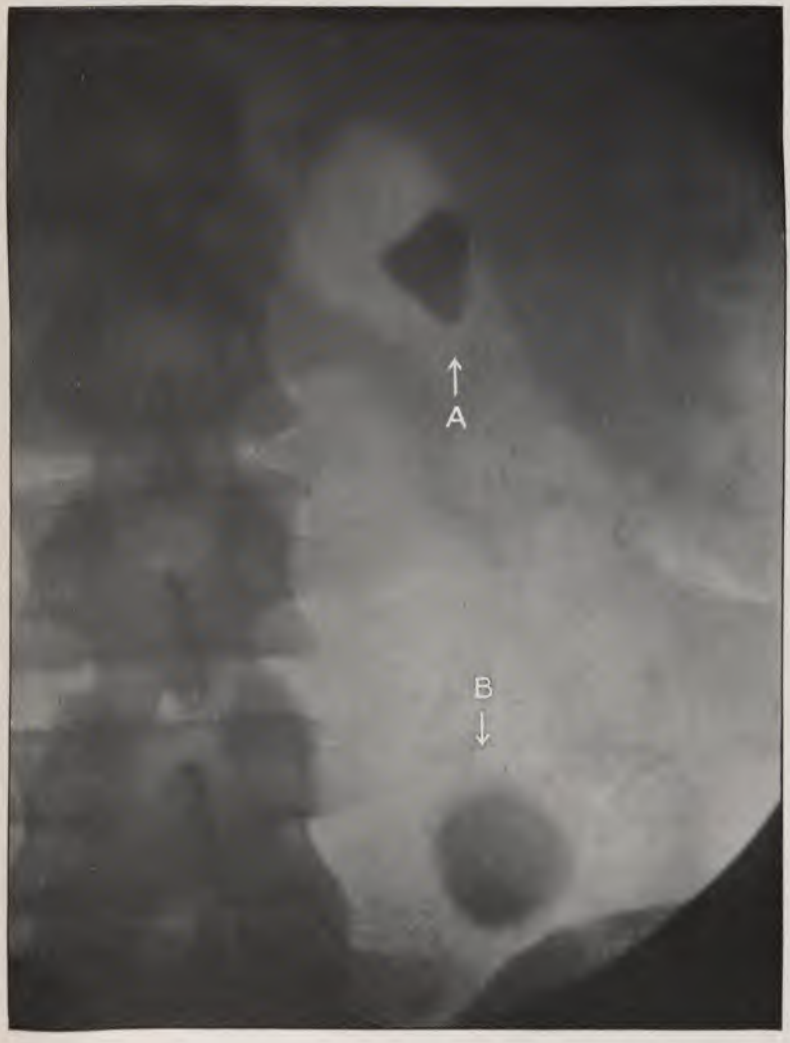

Bale & Danielsson, Ltd.

A. Renal Calculus. B. Large Calcified Gland.
X-Rayed by Dr. C. Thurstan Holland.

PLATE LXI.

One of my first cases of calcareous gland shadows is somewhat similar to that met with in Mr. Thurstan Holland's case.

I was assured by two radiographers, in 1902, that the shadow shown in Plate LXI represented a stone in the ureter, and as the patient, a young woman, aged 20, had had extreme pain in the right loin and along the course of the right ureter, I was urged to operate and remove the calculus. I pointed out the shape of the shadow and its hazy periphery, and argued that this, and its position, made it improbable that the trouble was ureteric. I operated, against my judgment, and removed a large meso-colic calcareous gland, and was somewhat surprised to find other gland in the same neighbourhood, apparently equally calcareous, which had not cast shadows.

I repeat, but cannot make a rule of it, with the slight knowledge I have: "Every calcified gland may not throw a shadow. If only one large shadow of a calcified gland is seen there are usually others which have not sufficiently obstructed the X-ray to cast a shadow."

Characteristic Calcareous Gland Shadows.

Rule 23.—When the shadows are multiple and arranged irregularly along the spinal column, or along the sharp brim of the true pelvis, they can safely be regarded as cast by calcareous glands.

Such an inference is obviously correct, and a casual glance at the next three radiographs will be sufficient to corroborate the truth of the rule.

But there is a third place where occasionally large, rounded shadows due to calcareous glands are seen; that is, on either side of the sacrum, just where the foramina of the nerves appear on that bone (*cf.* Plate LXVII).

PLATE LXII.

Multiple shadows of calcareous glands (white-arrowed which extend mainly along the left side of the spina column though a few are seen along the right.

From a patient who suffered from double psoas abscess which had been drained.

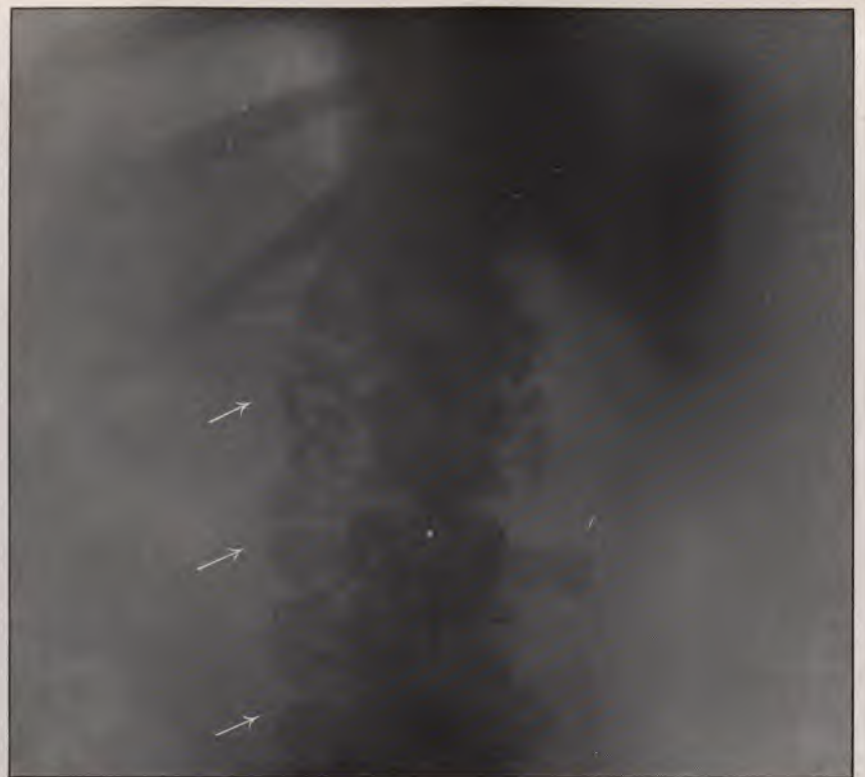

Shadows of packets of calcareous glands (white-arrowed) along side of spinal column.

PLATE LXIII.

PLATE LXIII.

Shadow of packets of calcareous glands (white-arrowed) which follow the lines of both internal iliac vessels.

From a patient who had had bilateral psoas abscess. (From the same patient as in Plate LXII.)

PLATE LXIV.

Small groups of minute calcareous glands (whi arrowed) which lie along the sharp edge of the pel brim. They are really by the side of the common ili vessels.

If the reader will refer to Plate XLV, page 88, it w be seen how exactly the position of these glands cor sponds to the line of the big vessels. The mark Δ in th plate was laid over the junction of the common iliacs, a this produced in the X ray the position of the brim the pelvis—exactly where these shadows lie.

PLATE LXIV.

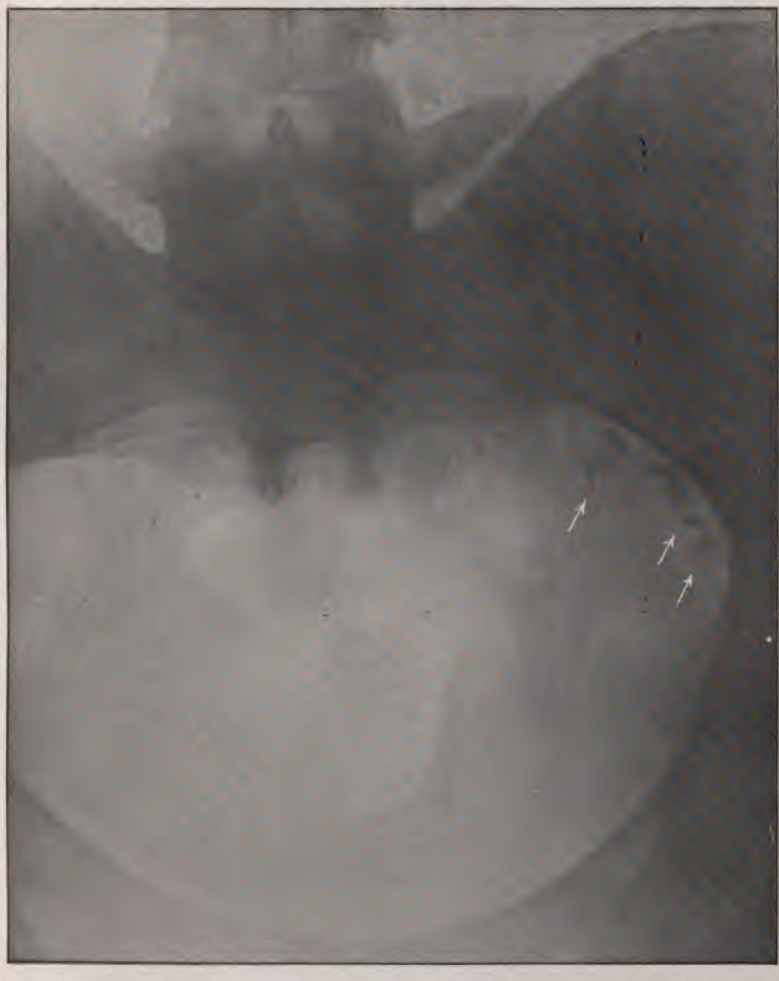

Shadows of small group of calcareous glands (white-arrowed) along the right pelvic brim.

PLATE LXV.

Shadows of calcified glands (white-arrowed). The single shadow to the left of the spine resembles a kidney-stone.

Concerning Shadows of Calcareous Glands which Resemble Urinary Stone very Closely.

An example of a cretified gland shadow which shows a very close resemblance to a urinary stone shadow may now be given.

Plate LXV shows a number of rounded shadows on both sides of the vertebral column. These shadows are white-arrowed.

Those ranged along the left side of the picture are obviously cast by calcareous glands, for they are numerous; they are grouped along the track of the ureter, and yet are so irregularly placed, and their long axes are directed at such varying angles to the long axis of the ureter, as to make it certain that they could not be in that channel.

The shadow I wish to draw attention to, however, is the single shadow (white-arrowed), which is situated on the right of the spinal column in the angle built by the last rib with that structure (Plate LXV).

This shadow is a calcified gland, though it resembles a stone in the kidney pelvis very closely.

This radiograph was taken *after* I had removed the kidney and ureter on this side for tuberculosis; hence the case is valuable as proving incontestably how easily one may mistake a calcified gland for stone in the kidney.

It should be noticed that the shadow is characteristic of renal stone in position, in outline, and in density.

A further illustration of calcified glands in the course of the upper ureter and how they could be proved to lie outside the ureter is given on page 117.

Sometimes the loin space shows irregular shadows cast by calcareous glands, and one or more of these may lie in the direct line of the upper ureter (Plate LXVI). Under these circumstances, though the majority of the shadows are obviously calcareous glands, it is wiser to ascertain the nature of the one or two which lie on the ureteric track. This can be easily done by an X-ray ureteric bougie (*vide* Plate LXIX, page 117).

Calcified Glands along the Track of the Lower Ureter.

I have not, myself, met with a calcified gland attached to the lower portion of the ureter so closely as to simulate a stone by the shadow it casts with the X ray, but Mr. Thurstan Holland[1] reports such a case which is, clinically, of much value, and I reproduce it.

"A gentleman had been more or less of an invalid for some years owing to the presence of pus in his urine, and to attacks, very sudden and severe, of pain and fever, followed by an increase in the quantity of pus. Several of these attacks had been serious enough to threaten his life. Repeated X-ray examinations at intervals always showed a shadow seen about the middle of the lower ureter as it crosses the pelvic area, and no other abnormal shadows could be found in any other part of the stone area. At the operation a calcareous gland was found *adherent to the ureter,* and in the ureter *at the same spot* was found a tiny calculus. The calcareous gland substance removed weighed 0·70 gramme, the calculus 0·022 gramme. It seems certain that the passage of this calculus was prevented by the pressure of the gland, and that at times more or less obstruction occurred, with attacks of pyelitis. Since the operation, nearly a year

[1] Thurstan Holland, "Some Difficulties in the X-Ray Diagnosis of Renal Calculus," 'Archives of the Röntgen Ray and Allied Phenomena,' August, 1907.

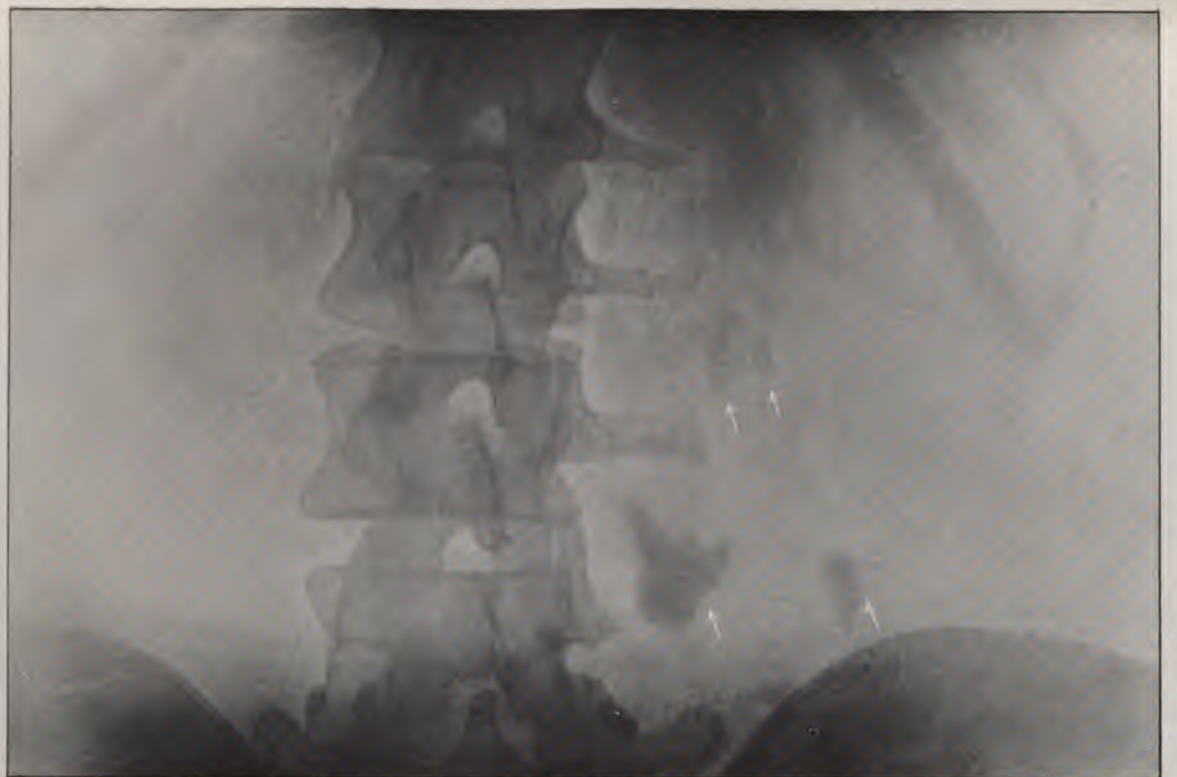

Shadows of calcareous glands in the right loin space.

Bale & Danielsson, Ltd.

ago, there have been no attacks of illness; and, although microscopically the urine still contains a few pus cells, which are supposed to be of kidney origin, the patient is perfectly well and has regained his health and strength."

How to Determine whether an Ambiguous Shadow in the Course of the Ureter is Cast by a Calculus within that Canal or by some Body outside it.

I have dealt with typical instances of ureteric stone (page 67). I have also given several well-marked radiograms of phleboliths in the pelvic area and of calcified glands along the course of the ureter, which very closely resemble ureteric stone. We are confronted, therefore, with this question, which is not merely of academic interest but of weighty importance both to the patient and to the credit of operative surgery. How are we to be certain in cases in which indefinite, non-characteristic shadows appear in the course of the ureter that we are dealing with ureteric stone? It cannot be to the patient's benefit or the surgeon's credit to make a huge extra-peritoneal flap, and search up and down the ureter for a stone which may not exist. No conscientious surgeon would feel justified in acting thus without at least a clear stereoscopic picture of the position of the shadow. Mr. Mackenzie Davidson has been all wise in insisting on this procedure. But even stereoscopy does not make the matter absolutely certain. Personally speaking, when I am in doubt—and I often am, even with a fine stereoscopic view of a ureteric shadow—I pass along the ureter a bougie which casts a shadow with the X ray. The patient is then radiographed with the bougie in position. As the bougie just fills the canal of the ureter, I can generally tell at once by tracing the ureteric shadow of the bougie as to whether a stone is in the ureter or not, for the shadow of a stone in the ureter will coalesce with that of the ureteric bougie, whilst the shadow of a phlebolith or a

calcified gland will lie quite away from the shadow of t ureteric bougie.

But more than this. The surgeon can often feel t grate of a stone in the ureter if the bougie passes it, can recognise an obstruction if the bougie meets with unsurmountable obstacle, as it often does when it stri a ureteric stone.[1]

When I published the expedient of the X-ray bougi did not know it had been resorted to by others. Bu opined that it had been, as it was so simple and easy skilled hands, and I could therefore hardly believe it h not been utilised in cases of doubtful shadows. The id was, however, practical, and as the procedure saves mu unnecessary mutilation I published it.[2] It may not out of place here to say that for some years I had be passing bougies up the ureters for sounding that chan for stone. Probably many others have been acting the same manner.

The idea, however, of radiographing a bougie imp meable to X ray did not occur to me until I was talki over a case with Mr. Mackenzie Davidson (page 11 I then promised to introduce one along the ureter c taining a soft core of metal, and he agreed to radiogra it in position.

Months later, on looking through Casper's book 'Cystoscopy,' I came across a picture of a metal-co catheter in the ureters and gathered that L. E. Schm and G. Kolischer (Chicago), and W. A. Hirschmann[3] h already carried out the procedure in so far as to utilise for detecting the presence of two kidneys.

[1] Or the surgeon may use Kelly's wax on to the head of the bou which may be examined for scratch marks after passing it.

[2] 'Brit. Med. Journ.,' June 17th, 1905.

[3] Leopold Casper, 'Handbuch der Cystoskopie,' p. 215.

PLATE LXVII.

The Use of the Radiographic Ureteric Bougie.

At first I used a ureteric catheter with a wire in it, passing it into the ureters of the male by the aid of a Nitze or an Albarran ureter-cystoscope, or in the female by means of the Kelly[1] method. But I became dissatisfied with the thinness of the shadow of the bougie and I enlisted Mr. Marshall's help. This gentleman made me a radiographic bougie,[2] which is solid, aseptic, and easily passed, and it proves very dense to X ray. It is marked off in inches so that the eye can tell how far it has passed up the ureter when it meets with a check, and its point is in the form of a bougie à boule so as to permit of Kelly's wax adhering to its end. Its broad shadow stands out boldly in the radiograph when X-rayed *in situ* (*q.v.* Plates XLVII, XLVIII, LVIII, and LXIX), and I find it infinitely better than my original expedient of a styletted ureteric catheter; moreover, in the female, by smearing a little cacao butter on the neck I have the chance of being able to get scratch marks of a ureteric calculus, as Kelly has pointed out, and in all cases by the sense of touch I can feel if the point is arrested by a calculus in the ureteric channel.

Case.—The first case in which I used a ureteric X-ray guide was brought to me by Dr. Bertrand Dawson. The patient was a nurse, and she had been suffering severely from right renal colic. Mr. Harnack, of the London Hospital Radiographic Department, had taken a radiograph of her right kidney and ureter, and a large irregular shadow had appeared in the pelvic area in the line of the right ureter (Plate LXVII). It was suggested that

[1] Kelly, 'Gynæcology,' vol. ii, p. 37.

[2] It can be obtained at John Bell and Croyden, 50, Wigmore Street, London. It is listed as "The Marshall shadowgraph ureteric bougie." Not long ago a French firm imitated this in appearance, but on placing the Marshall bougie and its imitation on photographic plates under the X ray the difference was remarkable: the French gave a very poor shadow. The radiograph of the compared bougies is in the Appendix C.

this shadow represented a stone in the ureter and that the obstruction caused by it was responsible for the acute attack of right renal colic. I demurred because the shadow was so large and irregular and because a smaller one lay *below* it. I argued that the ureter could hardly contain so irregular a stone, for most ureteric stones are oval, and that the smaller shadow lay below the larger, not above it, and if it was a stone the small one could easily have found its way to the bladder.

Still, there was the cause of the acute renal colic to be explained, and in the then state of our knowledge of X-ray shadows I requested that Mr. Mackenzie Davidson should radiograph and give us a second opinion. This was done by him, and the same shadows appeared on the plate. He then suggested that a bougie should be passed up to see if the canal was clear. It then struck me we could X-ray a *stylet*-catheter lying in position in both ureters. I passed one up either ureter, the right being arrested some way above the pelvic brim, and they were X-rayed *in situ* by Mr. Mackenzie Davidson.

Plate LXVIII shows the result. The catheter shadows are seen in curves; that on the right side passes away from the shadows which were thought to be stones, thus making it evident that these lay outside the ureter. (I do not apologise for these plates. They are the first taken, and I give them here as evidence of what was first attempted.)

I operated at the point where the X-ray bougie on the right side was arrested (a little manœuvre I invariably adopt), and I found at that point a small oxalate of lime stone blocking the right ureter. It was about three inches below the right renal pelvis. Having removed the stone I worked along the ureter to find the cause of the shadow. Finally I opened the peritoneum and discovered a large calcareous gland in the mesentery and a collection of small glands near, similarly calcified just where the shadows appeared on the negative.

The patient recovered.

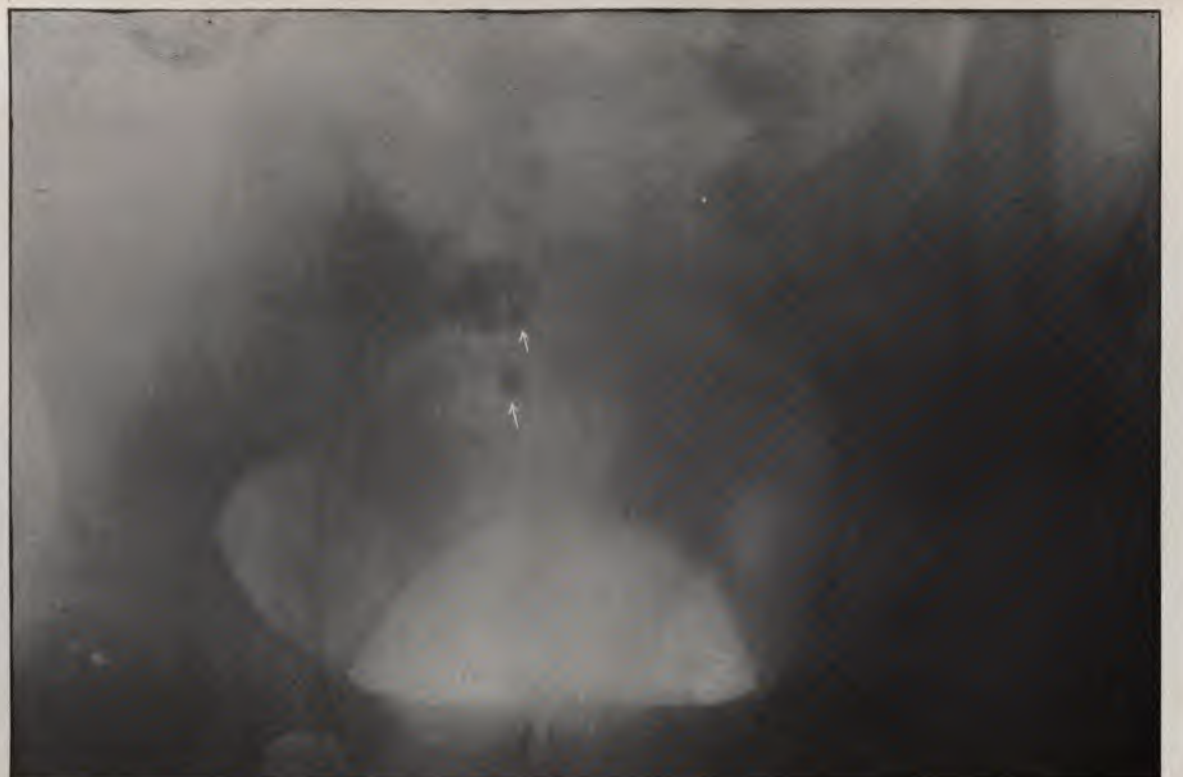

Thin line shadow crossing pelvic area is the stylet-catheter. It curves away from the calcified glands (white-arrowed), showing that these are outside ureter. (Radiographed by Mr. Mackenzie Davidson.)

Bale & Danielsson, Ltd.

PLATE LXIX.

Bate & Danielsson, Lt

PLATE LXIX.

This plate was taken from a woman, aged 25, who suffered extreme pain along the right ureter. Shadows (white-arrowed), obviously those of glands, are shown to the right of the spinal column, for they are irregular, far apart, and one is outside the line of the ureter. An X-ray bougie was passed to ascertain if the upper shadows were stones in the kidney. By some curious chance manipulation the tip of the ureteric bougie turned down into the lower pelvis, and is radiographed in this position. This was the first time I used a Marshall ureteric bougie.

Other plates illustrating the use of the ureteric bougie in cases exhibiting doubtful shadows will be found in the book (Plates XLVII, XLVIII, and LVIII).

The method is now used routinely, and I may add it has saved me on many occasions from interfering unnecessarily.

CHAPTER X.

ON THE SHADOWS OCCASIONALLY CAST BY CHRONIC TUBERCULOSIS OF THE UPPER URINARY TRACT.

It is rare, in my experience, for *acute* tuberculosis to cast any shadow with the present method of radiography. What the new instantaneous X-ray exposure (the Groedel-Horn method[1]) will reveal in this disease remains to be seen. But the present radiography (1908) does occasionally exhibit shadows cast by *chronic* tuberculous processes of the kidneys and ureter, and I venture to allude to them briefly, not only as complemental to the study of the radiography of calcified glands, but also because of the great importance in operative interference of this occasional guide to the existence of chronic changes in the kidney structure.

There are three main conditions of *chronic* tuberculosis of the urinary organs which interrupt the X ray in its passage through the body.

(1) Obsolesced tuberculous abscesses of the kidney (desiccated lime-putty mass).

(2) Phosphate of lime crusts or phosphatic concretions (ulcer sloughs permeated with phosphate of lime).

(3) Obsolescent tuberculous changes (diffused) of the

[1] Dr. Groedel, of Nauheim, and Mr. Horn, an engineer in the factory of Gebbert-Schall, have proved that a better quality of the picture of the heart, the stomach, and kidneys can be obtained with an exposure varying from one tenth to one fiftieth of a second than we have hitherto been able to obtain with exposures varying from two to two hundred seconds. Infinitely greater currents (viz. 220 volts, 90 amperes) are employed to obtain this result.

kidney which have become infiltrated with phosphate of lime.

Of these three, if I may judge from the small amount of material at my command, the first is the most commonly encountered.

1. Obsolesced Tuberculous Abscesses of the Kidney.

On exposing the tuberculous kidney to view at an operation one sometimes sees projecting slightly from the surface of the cortex a whitish bulging mass, easily recognisable as a chronic tuberculous abscess.

It may be that it is located at the upper or at the lower pole or even about the centre, but wherever it is, its whitish edge is so sharply separated from the ruddy-coloured cortex that the surgeon is not left in any doubt as to its nature.

The evacuated material varies according to its age and stage of obsolescence; generally, however, the pus cells having undergone albuminous and fatty changes, it is made up of fat, cholesterine, and phosphate of lime. It is either in a fluid form like cream or a more desiccated condition like putty. In the rarest instances the contents of the smallest, viz. about the size of a small monkey nut, may be found to have been changed to solid lime. I believe the semi-solid creamy abscess will be met with more often than the dry form.

Apparently these chronic abscesses obstruct the X-rays differently—some casting dense, well-formed shadows, others throwing patchy and indefinite shadows. This difference, I think, is due to the varying amount of phosphate of lime.

Nothing further need be said except to give two examples.

PLATE LXX.

L. F—, female, aged 21, was sent to me by Dr. Tilbury, of Peckham, in April, 1908, for intermittent pain in the right loin, which had troubled her for twelve months. For six months she had suffered from bladder irritability and pain on micturition.

On cystoscopy the bladder was shown to be superficially reddened, just as one sees it in tuberculosis of the kidney, but with this exception, it was fairly healthy. The right ureteric orifice was "dragged out,"[1] inflamed, and the channel, as felt *per vaginam*, was thickened.

The left ureteric orifice was healthy. Tubercle bacilli were present in the urine.

Diagnosis.—Right renal tuberculosis.

Radiography showed the upper pole of the right kidney, as judged by the deep shadow visible in the region of the last three lower ribs, to be changed into a large chronic tuberculous abscess.

Plate LXX shows a large irregular but dense shadow (white-arrowed) with a well-defined outline to be within the area of the lower ribs; a diagram is placed above the plate to render this appearance plainer.

[1] *cf.* Author, "On the Diagnostic Value of the Dragged-out Ureteric Orifice," 'Clinical Cystoscopy,' p. 500.

PLATE LXX.



Shadow of a tuberculous abscess (white-arrowed) in the upper pole of the kidney.

PLATE LXXI.

Vertical section of a tuberculous kidney showing the chronic abscess at upper pole—placed as in Radiograph LXX.

PLATE LXXI.

Nephrectomy was performed, and on splitting the organ this condition was verified (Plate LXXI).

The upper pole contained the chronic abscess, with its thickened wall and its creamy, gritty contents. The lower three quarters of the organ was in a state of acute miliary tuberculosis. The kidney was much enlarged, and had evidently suffered slightly from back-pressure exerted by a thickened ureter.

The second example I give shows the shadow to be irregular and to be much more pronounced towards the lower pole and the middle line than in the cortex (Plates LXXII *s* and LXXIII), the explanation of this inequality of density being that the lime constituents of the tuberculous abscess were massed along the pelvis and lower pole, and not collected in a distinct rounded sac, like a dilated calyx.

The history is interesting enough, from an operative aspect, to mention a little in detail.

F. E—, aged 21, was sent to me by Mr. Frank Corner, of Poplar, in 1902, with a diagnosis of mischief in the *left* kidney.

The patient complained of pain in the *left* side, and the urine contained one sixth albumen, casts and pus. The *left* kidney felt large and movable.

On radiography, a long, irregular opacity was seen in the *right* renal region (Plate LXXII *s*). It was obvious then that the right kidney was at fault and the left merely inflamed.

On exposing the right kidney it was seen to be distended and white, and on evacuating a quantity of creamy, gritty fluid it collapsed into a thin-walled fibrous sac. This shell of a kidney was removed with the upper part of the ureter. The ureter was hard and thickened, and its channel was blocked. Clearly, the pus, albumen, and casts which were found in the patient's urine had come from the *left* kidney, which was doing the work of the body, and that the condition of the right kidney was an example of latent tuberculosis of that organ, which had quietly been destroyed under the combined influence of tuberculosis and back-pressure from an obstructed ureter. The patient recovered, but was lost sight of.

2. Phosphate of Lime-crusts (Ulcer-sloughs which have become Permeated with Lime Phosphate).

It is rare for *true* stone to be found in a tuberculous

PLATE LXXII.

S. A long and irregular shadow of a chronic tuberculous deposit in the right kidney.

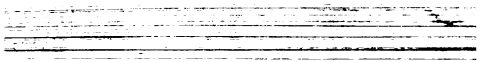

kidney, and if it is so found it has invariably formed prior to the incursion of the tuberculous mischief. Occasionally, however, hard phosphate of lime-crusts, due to the *débris* or sloughs which have separated in the deeper calices after erosion becoming permeated with lime-salts, are encountered, and these throw a faint shadow with the X ray. They usually form in the upper or lower calices, where chronic ulceration is most often met with. I have seen lime-crust shadows in favourable negatives, and have been able to diagnose them and draw them on the blackboard prior to the operation, but the shadow is so faint, even in well-marked cases, that I cannot reproduce it in a plate for illustration here without "touching up" the shadow. Such an exaggeration would only mislead, and I therefore allude to the subject only. The expert, however, should always be suspicious of disorganised kidney when a faint, small, irregular, plate-like shadow appears upon the negative in the kidney region in the lower and middle polar areas, and the clinician, on receiving such a negative from the radiographer, should systematically search for any evidence pointing to chronic tuberculosis of the kidney or chronic suppurative processes of that organ.

3. Lime Infiltration of Tuberculous Pyelo-nephritis.

It happens—I should consider it rare—that an entire kidney may become affected by changes of a tuberculous character, and may then become slowly permeated with phosphate of lime. The final change may be of so dense a character that the entire organ will obstruct the light, and then the shape of the kidney accurately appears on the negative.

In one case, which I give as an example, the ureter was affected by the same process and transformed into a dense, calcareous, stick-like tube, and it also appeared in the negative as a long stick-like shadow.

J. B. L—, a young gentleman aged 23, consulted me in 1904, relative to great frequency in urination and pain in the act. He had suffered from these symptoms for ten years. He was said to have had litholopaxy performed at the age of fifteen, but he obtained no relief from the operation and was never free from irritability of the bladder. He always rose five times at night to relieve himself.

The right lobe of the prostate had a small deposit of crude tubercle in its substance (as estimated by rectal examination). No tubercle bacilli were found in the various samples of urine examined, though there were some staphylococci and numerous micrococci. Cystoscopically, the bladder was eroded with ulceration and its capacity was much diminished.

Mr. Mackenzie Davidson radiographed the patient at my request and wrote me to the effect that the negative showed a very curious kidney darkening (Plate LXXIII) on the right side; unfortunately he had only taken the lower two thirds of the organ, but this was dense as if occupied by a uniform stoney mass (white-arrowed).

Bale & Danielsson, Ltd.

Shadow of the lower two thirds of a chronic tuberculous kidney (white-arrowed).
(Radiographed by Mr. Mackenzie Davidson.)

PLATE LXXIV.

He also added in his letter that there was a stick-like shadow along the line of the right ureter (Plate LXXIV), a condition which he said he had never seen before and did not understand. The clinical clue to this, I thought, was the condition of the bladder and the deposit of crude tubercle in the prostate. The patient received a written diagnosis of obsolesced tubercle of the right kidney and ureter, and the radiograph. He was advised to have the organ removed so as to diminish, if possible, the extreme bladder distress. He went very naturally for a second opinion, and then for others, and much doubt was expressed by the various consultants he called upon as to the correctness of the view taken, but he subsequently had nephrectomy performed by Professor Roux, of Lausanne, and I heard that caseating renal tuberculosis of the kidney was found.

A Clinical Rule based on X-Ray Shadow in Chronic Tuberculosis.

I do not need to dwell further upon shadows in chronic tuberculosis, interesting though the subject is, but I cannot refrain from adding an operative inference based on these shadows which may prove of some practical value in surgery. I have not seen the fact stated, and my method of drawing attention to it is probably crude, but the conclusion is sound, and based on a fairly large experience of operative work in tuberculosis of the urinary tract.

Clinical rule.—A tuberculous kidney which throws a well-marked shadow with the X ray has a hopeful prognosis, and a clean[1] removal of the kidney—other things being equal—will heal well.

It is probably the experience of expert surgeons that even an aseptic clean nephrectomy for tuberculosis does

[1] By a clean removal I understand a kidney taken aseptically and surgically from its bed without any incision or rupture of its cortex and without any leakage from the pelvis or divided ureter.

not always heal well; the wound apparently unites at first but breaks down after the fortnight and gapes. The expert surgeon may expect primary union and a sound scar barring a possible sinus to the ureteric division or ligature on the pedicle if a shadow is seen in the X ray. This axiom holds best with the desiccated or creamy obsolesced abscess, but it obtains even with the phosphatic crust cases.

The reason, I suspect, is that the presence of the lime phosphate indicates a *great power of natural repair*—a tendency to bury and render innocuous the tubercle bacillus; and it is for this reason I advocate lime, if lime is well borne, as part of the therapeutic treatment, always remembering that some patients do not possess the capacity for absorbing and depositing lime, just as they cannot take or utilise fat or sugar.

CHAPTER XI.

FAILURES.

PROBABLY every surgeon who started to rely upon radiography when the method was first made public met with disappointment and failure in accurately appreciating the true character of shadows, but all have noticed that these failures have lessened as the technique improved. It is therefore quite unnecessary for me to place on record my own initial failures.

But during the last five years, even with improved technique, I have had several cases in which shadows have appeared in the negative, and these I could not explain, even after operation. Probably this is also the experience of others, and with the element of uncertainty this also may be passed over without comment.

AN UNEXPLAINED PHENOMENON.

The form of failure which seems to me to need careful and searching examination is the action of certain inflamed kidneys upon the light. I do not wish to theorise or even to attempt an explanation, but I will state that some large branched stones are apparently rather translucent to the X ray when covered by an inflamed kidney or by condensed fat, or surrounded by pus, and are thus missed even by expert radiographists.

Some years ago Mr. Horace Townsend, of Cork, requested me to give an opinion upon a large painless right

renal tumour. The patient was a lady who was passing much pus in her urine.

I had the patient radiographed in London by a capable man and saw the negative. It was denser in the region of the tumour than elsewhere, but there were no shadow details pointing to stone. I advised operation. An enormous branched stone was found and removed by Mr. Townsend. He promptly took the stone, and being a keen radiographer himself he placed it under the opposite healthy loin and X-rayed the loin, with the result that a fine shadow of a branched stone, exact in every detail, appeared on the negative. He was good enough to write and let me know what he thought on the matter. He argued that if he (Mr. Townsend) could produce a fine shadow of the fragments of the stone when they were placed under the healthy loin, as good a shadow ought to have been thrown by the same stones when they were *in situ* in the diseased side. His expression of opinion was sufficiently strong to cause me to work at my failure. I felt that the expert radiographer I had called in to help me had failed, but I remembered that I had had a similar experience with the use of the X ray during the operation of nephro-lithotomy (*vide* p. 132). So I noted the occurrence and started upon the X ray of the dead kidney. This proved elusive.

PLATE LXXV.

The [illegible] so faint and indefinite that it cannot be reproduced in a plate, and [illegible] (Sky).

PLATE LXXV.

In April, 1906, a similar case of enlarged kidney came under my immediate care. It seems to me sufficiently valuable to record, for it may contain some clue to the unexplained easy transmission of light through a large branched calculus.

A woman was sent me with a diagnosis of right renal sarcoma. There was a large right renal tumour filling the loin and visible to the eye; pyelitis was present; the urine stank and contained one third pus.

I ascertained that the patient had had pain in the left loin eleven years ago, but that it had disappeared, and that she had been free from pain for ten years, but latterly her health and strength had failed.

Cystoscopy showed that the right ureteric orifice was pouring out pus and that occasionally it became plugged with a thick clump of pus. Obviously the right kidney was not sarcomatous but pyonephrous. The left ureteric orifice was healthy. Mr. Harnack X-rayed the patient, and in the negative I made out a faint shadow like a branched stone, but it was very faint (Plate LXXV). I remembered Mr. Townsend's case and made a mental resolve to follow his procedure.

PLATE LXXVI.

At the operation the tumour proved to be a disorganised right kidney imbedded in an extremely thick perinephric fatty capsule, the fat being especially dense and large in quantity.

The kidney was much thinned, but what was left of the cortex was densely indurated. There was a large branched, stinking phosphate-of-lime calculus. There was no collection of pus.

I placed the fragments of stone under the opposite loin of the patient, on a plate, and had the lamp adjusted mesially. The accompanying radiograph (Plate LXXVI) was taken.

It is astonishing how clearly the details of the fragments appear in the negative. Why should these details be lost when the stone was covered by the inflamed kidney and fat? Is it the fat only which alters the light transmission? My experience with the X ray in inflamed kidneys leads me to believe it is the kidney and not the fat which is at fault.

PLATE LXXVI.

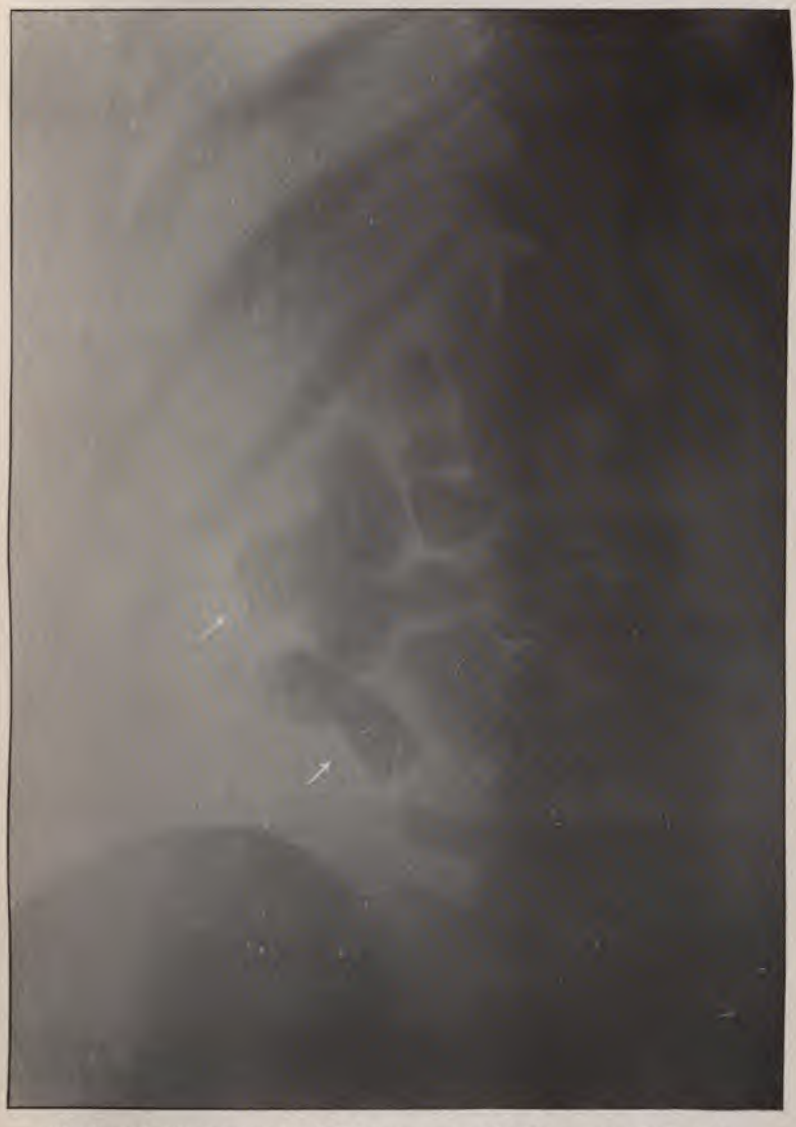

Shadows (white-arrowed) of the fragments of a large stone taken from the diseased kidney placed under the patient's opposite loin, and then radiographed.

PLATE LXXVII.

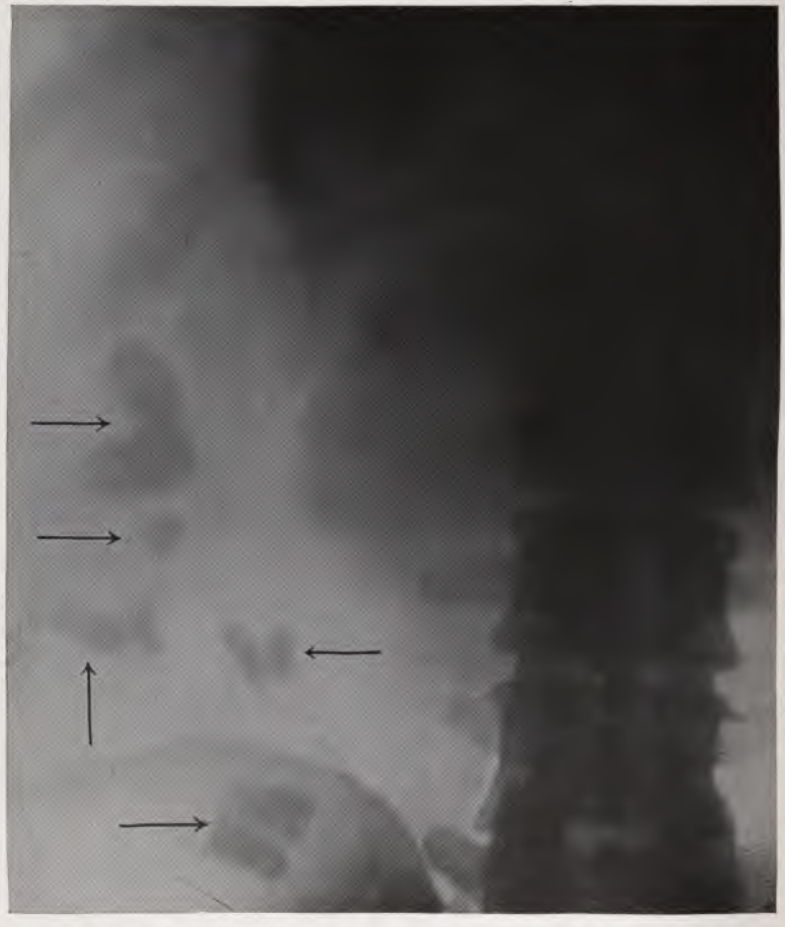

Radiograph of stones *outside* a chronically suppurating kidney. The shadows (black-arrowed) are *clearly* defined for contrast with Plate LXXV.

A Corroborative Case.

Not long ago another similar case in a man, aged 60, was brought to me. A tumour of the left side could be seen and felt in the left loin similar in every respect to that observed in the two patients I have just mentioned. The swelling was hard and fixed; there was a little pus in the urine. The radiographs taken of the left loin showed a most extraordinary collection of shadows, which shifted about with digital examination of the loin (Plate LXXVII).

It will be noticed that the lowest shadows blend with that of the iliac bone, whilst the others are far outside the mid-vertical line. What were the shadows? Certainly stone shadows—but where? I did not attempt to diagnose the kidney condition.

On opening the left loin an extremely thick and dense fatty capsule appeared. On cutting through this an inflamed kidney, filled with stinking pus, with great masses of indurated fat at the hilum, was revealed. The adhesions of the thickened fatty capsule were so great that I had to shell it out by subcapsular enucleation. It contained no stone. What, then, were the shadows so plainly seen in the radiograph?

A little search revealed the stump of the ureter. It was widely dilated and admitted the forefinger. A little way down the channel it suddenly opened into a huge abscess sac, with dense thickened walls; it was filled with grumous pus and urine, and in it were found the stones which had cast the shadows (Fig. 15). This sac extended outwards under the tissues of the loin and downwards to the inner side of the pelvic crest.

One must infer that at one time or another in the history of this kidney a block had taken place in the ureteric channel 2½ inches below its commencement. Ulcerative processes had destroyed the wall, and extravasation had taken place. One stone looked like a kidney stone—the oval; the others are so irregular that

it is doubtful if they formed in the kidney at all (Plate LXXVIII). Probably three stones formed on the fascial sloughs separating in the abscess sac, for it will be noticed that they are deeply indented like clothes-pegs and were formed folded round—so to speak—thick strands of the half-destroyed psoas parvus tendon. There are some

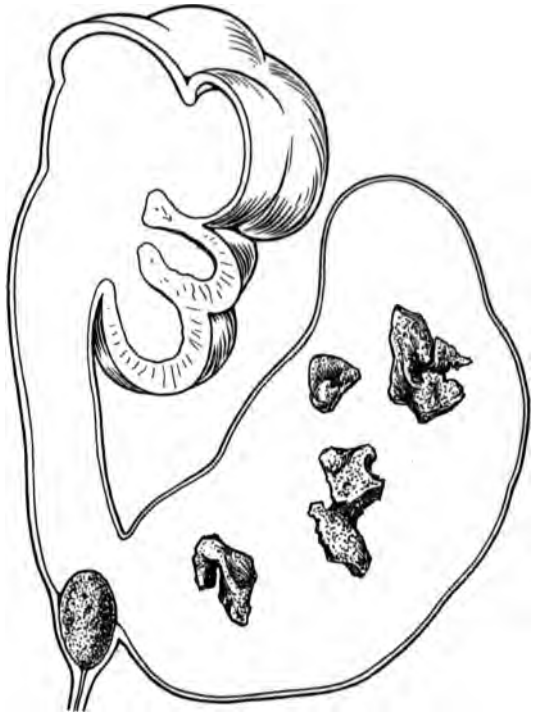

FIG. 15.

points of interest in these shadows, which centre mainly in their position outside the mid-vertical. But this is of no moment. The salient feature is the clear shadow definition of stones which were not *within* a thickened capsule and an inflamed kidney, but outside in an adventitious sac.

In this respect it is a complemental proof that certain inflamed kidneys hide stones by not obstructing the X ray.

PLATE LXXVIII.

Kidney stones removed from extra renal abscess represented in Fig. 15.

APPENDIX.

APPENDIX A.

Note on the Use of the X Ray during the Actual Time of Nephro-lithotomy.

Soon after the method of radiography was published I tried to use it during nephro-lithotomy, and published a small note upon the value of a radioscope[1] I had had made for this purpose (Plate LXXIX).

I soon found, however, that kidneys do not possess the same translucency—that in some the X ray penetrates and that in others it is blocked. I had on this account and because of difficulty of using the X ray in the theatre to relinquish the use of the method during operation, and have endeavoured to discover the cause for the varying densities which the diseased kidney exhibits to the X ray, but I have made no way with it and have been forced to leave the question to others who have more time at command.

[1] Author, 'Brit. Med. Journ.,' 1902, vol. ii, p. 117.

PLATE LXXIX.

PLATE LXXIX.

A method attempted by author in 1902, but discarded because of the varying densities of inflamed kidneys, and the difficulty of utilising the method in the operating theatre

APPENDIX B.

List of Bodies in which the Vesico-prostatic Plexuses were Injected and Dissected by Mr. Hurry Fenwick, *cf.* page 84.

Sex.	Age.	Vesico-prostatic system.	Died of.
Fœtus	8 mos.	Beautifully valved	?
Male	1¾ yrs.	Extremely well valved	Pneumonia.
,,	2½ ,,	Accurately valved	Measles.
,,	5 ,,	Healthy, venous system accurately valved	Croup.
,,	6 ,,	Beautifully valved	Acute general peritonitis (run over).
,,	6 ,,	Accurately valved	Diphtheria.
,,	7 ,,	,, ,,	Pulmonary tuberculosis.
,,	8 ,,	,, ,,	Broncho-pneumonia.
,,	10 ,,	,, ,,	Pyæmia.
,,	14 ,,	Well valved	Aortic disease.
,,	15 ,,	Accurately valved	Cerebro-spinal meningitis.
,,	17 ,,	,, ,,	Typhoid.
Female	17 ,,	,, ,,	Tuberculous peritonitis.
Male	18 ,,	A phlebolith	?
,,	18 ,,	Accurately valved	Pneumonia.
,,	25 ,,	Valve adhesions on right side, phlebolith left side	Tuberculous lung.
,,	26 ,,	Valve system destroyed	Malignant growth of lung, kidney, and prostate.
,,	27 ,,	Phlebolith right side	Cardio-vascular disease.
,,	28 ,,	Accurately valved	Bright's disease.
,,	30 ,,	Well-valved veins	?
,,	30 ,,	Imperfect valves	Mediastinal growth.
,,	30 ,,	Entire system defective	Pneumonia.
,,	30 ,,	Only partially valved	Mediastinal growth.
,,	31 ,,	Accurately valved	Cardiac hypertrophy.
,,	32 ,,	Valves degenerating	?
,,	34 ,,	Valved	Empyæma.
,,	36 ,,	Accurately valved	Chronic Bright's disease.
,,	36 ,,	Two phleboliths	Addison's disease.
,,	37 ,,	Phlebolith, extensively	Aortic disease.
,,	37 ,,	Valve system weakened	Pulmonary tuberculosis.
,,	38 ,,	Accurately valved	Vesical tubercle.
,,	38 ,,	Right-sided valves degenerating, left fairly healthy	?

Sex.	Age.	Vesico-prostatic system.	Died of.
Male	40 yrs.	Valves lost	Pneumonia.
,,	42 ,,	Valveless and a phlebolith	Fracture of spine.
,,	42 ,,	Phlebolith on left side of inverted Y-shaped vein	Perforating ulcer of stomach.
,,	44 ,,	Accurately valved	Acute suppurative nephritis.
,,	45 ,,	Perfect valvular system, as many as seven valves in the right vesico-prostatic plexus	Cardiac degeneration. Hæmorrhage into left corpus striatum.
,,	46 ,,	Valved	Perforating peritonitis.
,,	49 ,,	Valves destroyed	Tuberculosis.
,,	49 ,,	Phlebolith	Cardiac vascular change due to Bright's disease.
,,	50 ,,	Vesico-prostatic plexus destroyed, its place being taken by calculi and fibrous cords, but the bladder system all perfectly valved and varicosed so as to do the work of the obliterated vesico-prostatic plexus	Chronic Bright's disease.
,,	52 ,,	Valves gone generally	Miliary tubercle of bladder.
,,	52 ,,	Excellently valved system	Aortic atheroma.
,,	60 ,,	Phleboliths	Prostatic enlargement.
,,	67 ,,	Valved system gone	Cancer of stomach.
,,	67 ,,	Only partially valved	Emphysema and bronchitis.
,,	69 ,,	Commencing phleboliths	Aortic atheroma.
Female	76 ,,	Valves all lost	Strangulated femoral hernia.
,,	82 ,,	Valveless	Intra-capsular fracture of neck of femur.

PLATE LXXX.

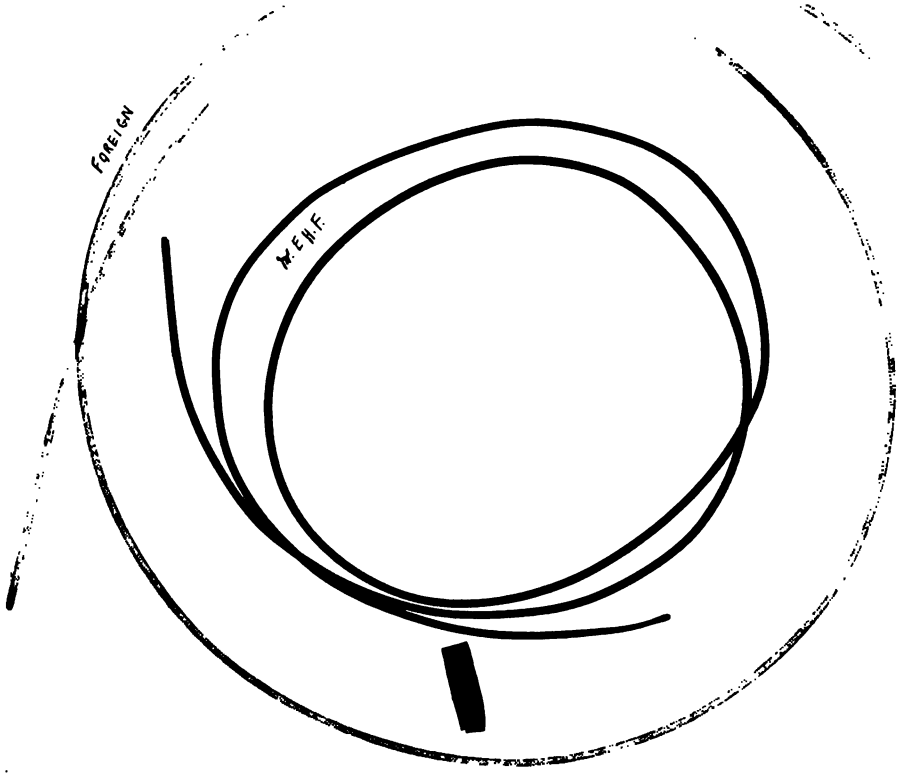

Comparison radiograph of shadowgraph bougies for ureteric examination.

Adlard & Son, Impr.

APPENDIX C.

PLATE LXXX.

A radiograph of two ureteric radiographic bougies. The one marked E.H.F., which stands out in a good black shadow, is the Marshall bougie made by Bell and Croydon, which is in use in England and America. The other, which shows a faint shadow and is marked FOREIGN, is made abroad, but now sold in England. It is obvious which is the better, and how important it is to secure a radiographic bougie which throws the blackest shadow.

INDEX

ADLARD AND SON, IMPR., LONDON AND DORKING.

No. 3.

J. & A. CHURCHILL

Recent Works for Students and Practitioners of Medicine.

LONDON:

7, Great Marlborough Street.

NOVEMBER, 1911.

INDEX.

FREE ON . . . APPLICATION.

1. Complete Illustrated Catalogue.
2. Catalogue of Science Books.

Anatomy & Physiology

A Treatise on Human Anatomy. By various Authors. Edited by Sir HENRY MORRIS, Bart., M.A., F.R.C.S., Past President of the Royal College of Surgeons, England; and J. PLAYFAIR MCMURRICH, A.M., Ph.D., Professor of Anatomy, University of Toronto. Fourth Edition. With 1025 Engravings, of which 319 are printed in 3 or 4 colours. 30*s.* net. Also issued in 5 parts. Parts I, II, and III, 8*s.* net each; and Parts IV and V, 5*s.* net each.

Anatomical Terminology, with Special Reference to the B.N.A. By LLEWELLYS F. BARKER, M.D., Professor of Medicine, Johns Hopkins University, Baltimore. With Illustrations and 2 Coloured Plates. 5*s.* net.

A Manual of Practical Anatomy. By the late Professor ALFRED W. HUGHES, M.B., M.C.Edin., Professor of Anatomy, King's College, London. Edited and completed by ARTHUR KEITH, M.D., Lecturer on Anatomy, London Hospital Medical College. In three parts, Part I, 10*s.* 6*d.* Part II, 8*s.* 6*d.* Part III, 10*s.* 6*d.*

Heath's Practical Anatomy: a Manual of Dis-sections. Edited by J. E. LANE, F.R.C.S., Surgeon and Lecturer on Anatomy at St. Mary's Hospital. Ninth Edition. 321 Engravings. 12*s.* 6*d.*

Clinical Applied Anatomy; or, The Anatomy of Medicine and Surgery. By CHARLES R. BOX, M.D., F.R.C.P.Lond., Physician to Out-patients, St. Thomas's Hospital, and W. MCADAM ECCLES, M.S.Lond., F.R.C.S.Eng., Surgeon, with charge of Out-patients, St. Bartholomew's Hospital. Illustrated by 45 Plates. 12*s.* 6*d.* net.

Essentials of Surface Anatomy. By CHARLES R. WHITTAKER, F.R.C.S., L.R.C.P., etc., Demonstrator of Anatomy, Surgeons' Hall, Edinburgh. *Second Edition, December*, 1911.

Text-Book of Anatomy for Nurses. By ELIZABETH R. BUNDY, M D. With a Glossary and 191 Illustrations. 7*s.* 6*d.* net.

Human Osteology. By LUTHER HOLDEN. Eighth Edition. Edited by CHARLES STEWART, F.R.S., and ROBERT W. REID, M.D., F.R.C.S. 59 Lithographic Plates and 74 Engravings. 16*s.* **Landmarks, Medical and Surgical.** Fourth Edition. 3*s.* 6*d.*

Elements of Human Physiology. By ERNEST H. STARLING, M.D., F.R.C.P., F.R.S., Jodrell Professor of Physiology in University College, London. Eighth Edition. 323 Illustrations. 12*s.* 6*d.* net.

A Course of Experimental Physiology. By N. H. ALCOCK, M.D., Prof. Physiol. McGill Univ., Montreal; and F. O'BRIEN ELLISON, M.D., B.A.O.Dub., Physiological Department, St. Mary's Hospital. With 36 Illustrations. 5*s.* net.

Practical Physiological Chemistry. By PHILIP B. HAWK, M.S., Ph.D., Professor of Physiological Chemistry in the University of Illinois. Third Edition. With Coloured Plates and 127 Figures. 16*s.* net.

The Cell as the Unit of Life, and other Lectures delivered at the Royal Institution, London, 1899–1902: an Introduction to Biology. By the late ALLAN MACFADYEN, M.D., B.Sc., Fullerian Professor of Physiology, Royal Institution, London. Edited by R. TANNER HEWLETT, M.D, F.R.C.P., D.P.H. 7*s.* 6*d.* net.

The Functional Inertia of Living Matter: a Contribution to the Physiological Theory of Life. By DAVID FRASER HARRIS, M.D., C.M., B.Sc.(Lond.), F.R.S.E., Physiological Department, University of Birmingham. 12 Illustrations. 5*s.* net.

Materia Medica & Pharmacy

A Text-Book of Pharmacology and Therapeutics, or the Action of Drugs in Health and Disease. By ARTHUR R. CUSHNY, M.A., M.D., F.R.S., Professor of Pharmacology in the University of London, etc. Fifth Edition. 61 Illustrations. 15*s*. net.

Materia Medica, Pharmacy, Pharmacology, and Therapeutics. By W. HALE WHITE, M.D., F.R.C.P., Physician to, and Lecturer on Medicine at, Guy's Hospital. Twelfth Edition. 6*s*. 6*d*. net.

A Text-Book of Materia Medica for Students of Medicine. By C. R. MARSHALL, M.D., Professor of Materia Medica, University of St Andrews. 127 Illustrations. 10*s*. 6*d*. net. **A Manual of Prescribing for Students and Practitioners.** 5*s*. net.

Southall's Organic Materia Medica. By JOHN BARCLAY, B.Sc.Lond. Seventh Edition by E. W. MANN. 7*s*. 6*d*. net.

A Text-Book of Materia Medica. By HENRY G. GREENISH, F.I.C., F.L.S., Professor of Pharmaceutics to the Pharmaceutical Society. Second Edition. 269 Illustrations. 15*s*. net. **The Microscopical Examination of Foods and Drugs, in the Entire, Crushed, and Powdered States.** Second Edition. 209 Illustrations. 12*s* 6*d*. net. **An Anatomical Atlas of Vegetable Powders.** 138 Illustrations. 12*s*. 6*d*. net.

Materia Medica, Step by Step. By A. W. NUNN. 3*s*. 6*d*. net.

Practical Pharmacy. By E. W. LUCAS, F.I.C., F.C.S. Second Edition. 224 Illustrations. 12*s*. 6*d*. net.

BY THE SAME AUTHOR.

The Book of Prescriptions (Beasley) with an Index of Diseases and Remedies. Ninth Edition. 6*s*. net.

The Book of Receipts: containing a Veterinary Materia Medica, a Pharmaceutical Formulary, a Photographic Formulary, a Synopsis of Practical Methods employed in the Examination of Urine, Milk, Potable Waters, Sputum, etc. With 10 Plates 7*s*. 6*d*. net.

First Lines in Dispensing. 93 Illustrations. 3*s*. 6*d*. net.

The National Standard Dispensatory. By H. A. HARE, B.Sc., M.D., and others. 478 Illustrations. 31*s*. 6*d*. net.

Medical and Pharmaceutical Latin for Students of Pharmacy and Medicine. By REGINALD R. BENNETT, Pharmacist and Teacher of Pharmacy at University College Hospital, London. 6*s*. net.

A Companion to the British Pharmacopœia. By PETER WYATT SQUIRE, F.L.S., F.C.S. Eighteenth Edition. 14*s*. net. **Pocket Edition.** 7*s*. 6*d*. net. **The Pharmacopœias of Thirty of the London Hospitals.** Arranged in Groups for comparison. Eighth Edition. 5*s*. net.

The Pharmaceutical Formulary: a Synopsis of the British and Foreign Pharmacopœias. By HENRY BEASLEY. Twelfth Edition by J. OLDHAM BRAITHWAITE. 6*s*. 6*d*.

Tuson's Veterinary Pharmacopœia. Sixth Edition. Edited by JAMES BAYNE, F.C.S. 7*s*. 6*d*. net.

Year-Book of Pharmacy. Annually, 10*s*. net.

Hygiene & Bacteriology

The Theory and Practice of Hygiene. (NOTTER and FIRTH.) By R. H. FIRTH, Lt.-Col. R.A.M.C., F.R.C.S., Officer in Charge of the School of Army Sanitation, Aldershot. Third Edition. 22 Plates (some of which are in colours) and 200 other Illustrations. 21*s.* net.

BY THE SAME AUTHOR.

Military Hygiene: a Manual of Sanitation for Soldiers. With 40 Illustrations. 3*s.* 6*d.* net.

Manual of Hygiene. By W. H. HAMER, M.D., Lecturer on Public Health, St. Bartholomew's Hospital; Assistant Medical Officer of Health of the County of London. 93 Illustrations. 12*s.* 6*d.* net.

Lessons on Elementary Hygiene and Sanitation, with Special Reference to the Tropics. By W. T. PROUT, C.M.G., M.B., C.M.(Edin.), Hon. Lecturer School of Tropical Medicine, Liverpool. Second Edition. With 60 Illustrations. 2*s.* 6*d.* net.

Domestic Hygiene for Nurses. With some Physics and Chemistry. By FRED J. SMITH, M.D., F.R.C.P., Physician to the London Hospital. 18 Illustrations. 2*s.* 6*d.* net.

The Effects of Borax and Boric Acid on the Human System. Third Treatise. With Diagrams. By Dr. OSCAR LIEBREICH. 5*s.* net.

The Action of Boron Preservatives on Bacillus Coli and Allied Microbes. By E. KLEIN, M.D., F.R.S., Lecturer on Advanced Bacteriology, St. Bartholomew's Hospital. 6*d.* net.

A Simple Method of Water Analysis. By JOHN C. THRESH, M.D.Vic., D.Sc.Lond. Sixth Edition. 2*s.* 6*d.* net.

BY THE SAME AUTHOR.

The Examination of Waters and Water Supplies. 19 Plates and 11 Figures in the Text. 14*s.* net.

ALSO, WITH ARTHUR E. PORTER, M.D., M.A.CANTAB.

Preservatives in Food and Food Examination. 8 Plates. 14*s.* net.

Foods and their Adulteration. By HARVEY W. WILEY, M.D., Ph.D. Second Edition. With 11 Coloured Plates and 87 other Illustrations. 21*s.* net.

A Manual of Bacteriology, Clinical and Applied. By R. TANNER HEWLETT, M.D., Professor of General Pathology and Bacteriology in King's College, London. Fourth Edition. 26 Plates and 69 Figures in the Text. 10*s.* 6*d.* net.

BY THE SAME AUTHOR.

Serum and Vaccine Therapy, Bacterial Thera- peutics and Prophylaxis, Bacterial Diagnostic Agents. Second Edition. 32 Figures. 7*s.* 6*d.* net.

Clinical Diagnostic Bacteriology, including Serum- and Cyto-diagnosis. By ALFRED C. COLES, M.D., D.Sc., F.R.S.E. 2 Coloured Plates. 8*s.* net.

Lessons in Disinfection and Sterilisation. By F. W. ANDREWES, M.D., F.R.C.P., Lecturer on Pathology, St. Bartholomew's Hospital. Second Edition. 31 Illustrations. 3*s.* 6*d.* net.

Pathology & Psychology Dictionaries

Pathology, General and Special, for Students of Medicine. By R. TANNER HEWLETT, M.D., F.R.C.P., D.P.H., Professor of General Pathology and Bacteriology in King's College, London. 31 Plates and 13 Illustrations in Text. Second Edition. 10*s*. 6*d*. net.

A Manual of General or Experimental Pathology. By W. S. LAZARUS-BARLOW, M.D., F.R.C.P., Director of the Cancer Research Laboratories, Middlesex Hospital. Second Edition. 21*s*. net.

BY THE SAME AUTHOR.

The Elements of Pathological Anatomy and Histology for Students. 24*s*. net.

Surgical Pathology and Morbid Anatomy. See p. 8.

Manual of Clinical Pathology. By R. WEISS, M.A., Ph.D., F.C.S., in collaboration with G. HERSCHELL, M.D., and A. CHARLES, F.R.C.S. 16 Illustrations. 2*s*. net.

Post-mortem Manual. A Handbook of Morbid Anatomy and Post-mortem Technique. By C. R. BOX, M.D., F.R.C.P., F.R.C.S., Lecturer on Applied Anatomy, St. Thomas's Hospital. 19 Illustrations. 6*s*. net.

The Pathologist's Handbook: a Manual for the Post-mortem Room. By T. N. KELYNACK, M.D. 126 Illustrations. 4*s*. 6*d*.

Psychological Medicine. By MAURICE CRAIG, M.A., M.D., F.R.C.P., Physician and Lecturer on Mental Diseases, Guy's Hospital. 22 Plates. 12*s*. 6*d*. net.

Mental Diseases: Clinical Lectures. By Sir T. S. CLOUSTON, M.D., F.R.C.P.Edin., Lecturer on Mental Diseases in the University of Edinburgh. Sixth Edition. 30 Plates. 14*s*. net.

The Force of Mind; or, the Mental Factor in Medicine. By ALFRED T. SCHOFIELD, M.D., Hon. Physician to Friedenheim Hospital. Third Edition. 5*s*. net. **Unconscious Therapeutics; or, The Personality of the Physician.** Second Edition. 5*s*. net. **The Management of a Nerve Patient.** 5*s*. net.

The Journal of Mental Science. Published Quarterly, by Authority of the Medico-Psychological Association. 5*s*. net.

Dictionary of Medical Terms: English, French, German. Edited by PAUL BLASCHKE. 8*s*. net. **Dictionary of Medical Conversation; English-German,** 4*s*. net. **German-English,** 4*s*. net.

A German-English Dictionary of Terms used in Medicine and the Allied Sciences. By HUGO LANG, B.A., and BERTRAM ABRAHAMS, M.B., B.Sc., F.R.C.P. 15*s*. net.

Dunglison's Dictionary of Medical Science. By THOMAS L. STEDMAN, M.D. Twenty-third Edition. 577 Illustrations, including 84 page-plates. 34*s*. net.

A Medical Vocabulary. By R. G. MAYNE, M.D., LL.D. Seventh Edition, by W. W. WAGSTAFFE, B.A., F.R.C.S., and G. D. PARKER M.B. 12*s*. 6*d*.

Medicine

A Text-Book of Medicine. Begun by the late C. HILTON FAGGE, M.D.; completed and re-written by P. H. PYE-SMITH, M.D., F.R.S. Fourth Edition. 2 vols. 42*s*.

The Practice of Medicine. By FREDERICK TAYLOR, M.D., F.R.C.P., Consulting Physician to, and Lecturer on Medicine at, Guy's Hospital. Ninth Edition. 8 Skiagram Plates and 67 Illustrations. 18*s*. net. **Some Disorders of the Spleen.** 3*s*. net.

A Short Practice of Medicine. By ROBERT A. FLEMING, M.A., M.D., F.R.C.P.E., F.R.S.E., Lecturer on Practice of Medicine, School of the Royal Colleges, Edinburgh; Assistant Physician, Royal Infirmary, Edinburgh. Second Edition. 48 Illustrations (10 coloured). 12*s*. 6*d*. net.

The Practice of Medicine. By M. CHARTERIS, M.D. Professor of Therapeutics and Materia Medica in the University of Glasgow. Ninth Edition. Edited by F. J. CHARTERIS, M.D., Ch.B. Illustrated. 9*s*. 6*d*. net.

A Medical Vademecum, in German and English. By B. LEWIS. With a Preface by Prof. Dr. A. POLITZER. 15*s*. net.

A Manual of Physical Diagnosis. By BREFNEY R. O'REILLY, M.D., C.M., M.R.C.S.Eng., L.R.C.P.Lond., Demonstrator in Clinical Medicine and in Pathology, University of Toronto With 6 Plates and 49 other Illustrations. 8*s*. 6*d*. net.

A Dictionary of Medical Treatment for Students and Junior Practitioners. By ARTHUR LATHAM, M.D.Oxon., F.R.C.P.Lond., Physician and Lecturer on Medicine at St George's Hospital. 6*s*. 6*d*. net.

Text-Book of Medical Treatment (Diseases and Symptoms). By NESTOR I. C. TIRARD, M.D., F.R.C.P., Professor of the Principles and Practice of Medicine, King's College, London. 15*s*.

A Manual of Family Medicine and Hygiene for India. Published under the Authority of the Government of India. By Sir WILLIAM J. MOORE, K.C.I.E., M.D. Seventh Edition edited by Major J. H. TULL WALSH, I.M.S. 70 Engravings. 6*s*. net.

Waring's Bazaar Medicines of India. By Lt.-Col. C. P. LUKIS, I.M.S., Principal of the Medical College, Calcutta. Sixth Edition. 6*s*. net.

The Blood: how to Examine and Diagnose its Diseases. By ALFRED C. COLES, M.D., D.Sc., F.R.S.Edin. Third Edition. 7 Coloured Plates. 10*s*. 6*d*. net.

Lectures on Medicine to Nurses. By HERBERT E. CUFF, M.D., F.R.C.S., late Medical Superintendent, North-Eastern Fever Hospital, London. Fifth Edition. 29 Illustrations. 3*s*. 6*d*. net.

How to Examine the Chest. By SAMUEL WEST, M.D., F.R.C.P., Physician to St. Bartholomew's Hospital. Third Edition. 46 Engravings. 5*s*.

Medicine

A System of Treatment. By many writers. Edited by ARTHUR LATHAM, M.A., M.D., F.R.C.P., Physician and Lecturer on Medicine, St. George's Hospital, and T. CRISP ENGLISH, M.B., B.S., F.R.C.S., Senior Assistant Surgeon, St. George's Hospital. In 4 Vols. Vols. I and II, General Medicine and Surgery; Vol. III, Special Subjects; Vol. IV, Gynæcology and Obstetrics. Price £1 1s. net per volume. Detailed prospectus upon application. *Ready early in* 1912.

Vicious Circles in Disease. By J. B. HURRY, M.A., M.D. With 10 Illustrations. 6s. net.

Ulcer of the Stomach and Duodenum. By SAMUEL FENWICK, M.D., F.R.C.P., and W. SOLTAU FENWICK, M.D., B.S. 55 Illustrations. 10s. 6d. **Cancer and other Tumours of the Stomach.** 70 Illustrations. 10s. 6d.

On Carbohydrate Metabolism, with an Appendix on the Assimilation of Carbohydrate into Proteid and Fat, followed by the Fundamental Principles and the Treatment of Diabetes dialectically discussed. By FREDERICK W. PAVY, M.D., LL.D., F.R.S., F.R.C.P., Consulting Physician to Guy's Hospital. With 8 Plates. 6s. net.

The Schott Methods of the Treatment of Chronic Diseases of the Heart. By W. BEZLY THORNE, M.D., M.R.C.P. Fifth Edition. Illustrated. 5s. net.

The Clinical Examination of Urine, with an Atlas of Urinary Deposits. By LINDLEY SCOTT, M.A., M.D. 41 original Plates (mostly in colours). 15s. net.

Urine Examination made easy. By T. CARRUTHERS, M.B., Ch.B. Second Edition. 1s. 6d. net.

Rational Organotherapy. Translated from the Russian Text by Professor Dr. A. VON POEHL, Professor PRINCE J. VON TARCHANOFF, Dr. ALF VON POEHL, and Dr. P. WACHS. Vol. I. 7s. 6d. net.

On Gallstones, or Cholelithiasis. By E. M. BROCKBANK, M.D.Vict., M.R.C.P.Lond. 7s.

Obstinate Hiccough: the Physiology, Pathology, and Treatment. By L. F. B. KNUTHSEN, M.D.Edin. 6s.

On Syphonage and Hydraulic Pressure in the Large Intestine. By RALPH WINNINGTON LEFTWICH, M.D. 3s. net.

Uric Acid as a Factor in the Causation of Disease. By ALEXANDER HAIG, M.D., F.R.C.P., Physician to the Metropolitan Hospital. Seventh Edition. 75 Illustrations. 14s. net. **Uric Acid in the Clinic. A Clinical Appendix to 'Uric Acid as a Factor in the Causation of Disease.'** 5s. net. **Uric Acid, an Epitome of the Subject.** Second Edition. 2s. 6d. net. **Diet and Food considered in relation to Strength and Power of Endurance, Training, and Athletics.** Sixth Edition. 2s. net.

Surgery

The Practice of Surgery. By W. G. Spencer, M.S., F.R.C.S., Surgeon and Lecturer on Surgery, Westminster Hospital, and G. E. Gask, F.R.C.S., Assistant Surgeon and Demonstrator of Practical Surgery, St. Bartholomew's Hospital. 28 Skiagram Plates. 20 Colour Plates. 707 Text-figures. 22*s.* net.

Surgical Pathology and Morbid Anatomy. By Sir Anthony A. Bowlby, F.R.C.S., Surgeon to St. Bartholomew's Hospital, assisted by F. W. Andrewes, M.D., Lecturer on Pathology, St. Bartholomew's Hospital. Fifth Edition. 196 Engravings. 10*s.* 6*d.* net.

A Manual of Surgical Diagnosis. By James Berry, B.S.Lond., F.R.C.S., Surgeon to, and Lecturer on Surgery at, the Royal Free Hospital. 6*s.* net.

A Synopsis of Surgery. By R. F. Tobin, Surgeon to St. Vincent's Hospital, Dublin. Second Edition. Interleaved, leather binding. 6*s.* 6*d.*

Ovariotomy and Abdominal Surgery. By Harrison Cripps, F.R.C.S., Surgical Staff, St. Bartholomew's Hospital. Numerous Plates. 25*s.*

BY THE SAME AUTHOR.

On Diseases of the Rectum and Anus, including the Fifth Edition of the Jacksonian Prize Essay on Cancer. Third Edition. With 13 Plates and 34 Illustrations. 10*s.* 6*d.* net.

ALSO

Cancer of the Rectum, especially considered with regard to its Surgical Treatment. Jacksonian Prize Essay. Fifth Edition. With 13 Plates and several Engravings. 5*s.* net.

Diseases of the Rectum, Anus, and Sigmoid Colon. By F. Swinford Edwards, F.R.C.S., Senior Surgeon to St. Mark's Hospital for Fistula and other Diseases of the Rectum. Third Edition. 102 Illustrations. 10*s.* 6*d.* net.

A Manual of Minor Surgery and Bandaging. Fourteenth Edition of Heath's. By Bilton Pollard, F.R.C.S., Surgeon to University College Hospital. 250 Engravings. 7*s.* 6*d.* net.

Injuries and Diseases of the Jaws. By Christopher Heath, F.R.C.S. Fourth Edition. Edited by Henry Percy Dean, M.S., F.R.C.S., Assistant Surgeon to the London Hospital. 187 Wood Engravings. 14*s.*

BY THE SAME AUTHOR.

Clinical Lectures on Surgical Subjects delivered at University College Hospital. First Series, 6*s.*; Second Series, 6*s.*

An Essay on the General Principles of the Treatment of Spinal Curvatures. By R. Heather Bigg. Illustrated by Photographs and Sketches. 5*s.* net.

Surgery & Anæsthetics

A System of Treatment. In 4 Vols. By A. LATHAM and T. CRISP ENGLISH. See page 7.

The Operations of Surgery. By W. H. A. JACOBSON, M.Ch.Oxon., F.R.C.S., Consulting Surgeon Guy's Hospital, and R. P. ROWLANDS, M.S.Lond., F.R.C.S., Assistant Surgeon, Guy's Hospital. Fifth Edition. 2 vols. 777 Illustrations. 42*s.* net.

Abdominal Pain: its Causes and Clinical Significance. Second Edition. By ALFRED ERNEST MAYLARD, M.B.Lond. and B.S., Senior Surgeon to the Victoria Infirmary, Glasgow. 7*s.* 6*d.* net.

BY THE SAME AUTHOR.

Abdominal Tuberculosis. 57 Illustrations. 12*s.* 6*d.* net.

Clinical Essays and Lectures. By HOWARD MARSH, F.R.C.S., Professor of Surgery in the University of Cambridge. 26 Illustrations. 7*s.* 6*d.*

Hernia, its Cause and Treatment. By R. W. MURRAY, F.R.C.S., Surgeon, David Lewis Northern Hospital. Second Edition. 62 Illustrations. 6*s.* net.

Modern Bullet-Wounds and Modern Treatment, with Special Regard to Long Bones and Joints, Field Appliances and First Aid. By Major F. SMITH, D.S.O., R.A.M.C. 3*s.* net.

Surgical Emergencies. By PAUL SWAIN, F.R.C.S., Surgeon to the South Devon and East Cornwall Hospital. Fifth Edition. 149 Engravings. 6*s.*

Chloroform: a Manual for Students and Practitioners. By EDWARD LAWRIE, M.B.Edin., Lieut.-Col. I.M.S., Residency Surgeon, Hyderabad. Illustrated. 5*s.* net.

Neurology & Urinary Disorders

A Text-Book of Nervous Diseases. By W. ALDREN TURNER, M.D, F.R.C.P., Physician and Lecturer on Neurology, King's College Hospital, and T. GRAINGER STEWART, M.B., M.R.C.P., Assistant Physician, National Hospital for Paralysed and Epileptic. 1-8 Illustrations. 18*s*. net.

Paralysis and other Nervous Diseases in Childhood and Early Life. By JAMES TAYLOR, M.D., F.R.C.P., Physician National Hospital for Paralysed and Epileptic, Queen Square. 74 Illustrations. 12*s*. 6*d*. net.

A Manual of Diseases of the Nervous System.
By SIR WILLIAM R. GOWERS, M.D., F.R.S.

VOL. I.—**Nerves and Spinal Cord.** Third Edition, by the Author and JAMES TAYLOR, M.D., F.R.C.P. 192 Engravings. 15*s*.

BY THE SAME AUTHOR.

Subjective Sensations of Sight and Sound, Abiotrophy, and other Lectures on Diseases of the Nervous System. 18 Illustrations. 6*s*. net.

ALSO

Epilepsy and Other Chronic Convulsive Diseases. their Causes, Symptoms, and Treatment. Second Edition. 10*s*. 6*d*.

ALSO

The Borderland of Epilepsy, Faints, Vagal Attacks, Vertigo, Migraine, Sleep Symptoms, and their Treatment. 4*s*. 6*d*. net.

Text-Book of Nervous Diseases and Psychiatry. By CHARLES L. DANA, A.M., M.D., LL.D., Professor of Nervous Diseases in Cornell University Medical College. Seventh Edition. With 3 Plates and 261 Text-figures. 25*s*. net.

Selected Papers on Stone, Prostate, and other Urinary Disorders. By REGINALD HARRISON, F.R.C.S., Surgeon to St. Peter's Hospital. 15 Illustrations. 5*s*.

By E. HURRY FENWICK, F.R.C.S., Surgeon to the London Hospital.

A Handbook of Clinical Cystoscopy. 31 Plates and 144 Figures in the Text. (*Reprinting.*)

Atlas of Electric Cystoscopy. 34 Coloured Plates. 21*s*. net.

The Value of Radiography in the Diagnosis and Treatment of Urinary Stone. With 80 Plates. 10*s*. 6*d*. net.

Obscure Diseases of the Urethra. 63 Illustrations. 6*s*. 6*d*.

Operative and Inoperative Tumours of the Urinary Bladder. 39 Illustrations. 5*s*. net.

Tumours of the Urinary Bladder. Fasc. I. 5*s*. net.

Ulceration of the Bladder, Simple, Tuberculous, and Malignant: a Clinical Study. Illustrated. 5*s*.

Midwifery & Gynæcology

The Practice of Midwifery. By ALFRED L. GALABIN, M.A., M.D., F.R.C.P., Consulting Obstetric Physician to Guy's Hospital, and G. F. BLACKER, M.D., F.R.C.S., F.R.C.P., Obstetric Physician to University College Hospital. Seventh Edition. 503 Engravings. 18*s*. net.

Manual of Midwifery. By T. W. EDEN, M.D., C.M.Edin., F.R.C.P.Lond., Obstetric Physician and Lecturer on Practical Midwifery, Charing Cross Hospital. Third Edition. 339 Illustrations in the Text. 15*s*. net.

BY THE SAME AUTHOR.

Manual of Gynæcology. 272 Illustrations. 18*s*. net.

A Short Practice of Midwifery, embodying the Treatment adopted in the Rotunda Hospital, Dublin. By HENRY JELLETT, M.D., B.A.O.Dub., Master, Rotunda Hospital, Dublin. Fifth Edition. 4 Coloured Plates and 200 Illustrations. 10*s*. 6*d*. net.

BY THE SAME AUTHOR.

A Short Practice of Midwifery for Nurses, with a Glossary of the Medical Terms used in the Book, and the Regulations of the C.M.B. Third Edition. 4 Coloured Plates and 164 Illustrations. 6*s*. 6*d*. net.

A Manual for Midwives. By C. J. N. LONGRIDGE, M.D., M.R.C.P., F.R.C.S., Examiner Central Midwives' Board. 3 Plates and 47 Illustrations. 3*s*. 6*d*. net.

A Short Manual for Monthly Nurses. By CHARLES J. CULLINGWORTH, M.D., F.R.C.P., Obstetric Physician to St. Thomas's Hospital. Sixth Edition. 1*s*. 6*d*. net.

A Text-Book of Embryology. By F. R. BAILEY, A.M., M.D., Adjunct Professor of Histology and Embryology, College of Physicians and Surgeons, Columbia University, and A. M. MILLER, A.M., Instructor in Histology and Embryology, College of Physicians and Surgeons, Columbia University. 515 Illustrations. 21*s*. net.

A Laboratory Text-Book of Embryology. By C. S. MINOT, LL.D., D.Sc., Professor of Comparative Anatomy, Harvard Medical School. Second Edition. 262 Illustrations. 16*s*. net.

A Short Practice of Gynæcology. By HENRY JELLETT, M.D., B.A.O.Dub., Master, Rotunda Hospital, Dublin. Third Edition. 310 Illustrations (some coloured). 12*s*. 6*d*. net.

Outlines of Gynæcological Pathology and Morbid Anatomy. By C. HUBERT ROBERTS, M.D.Lond., Physician to the Samaritan Free Hospital for Women. 151 Illustrations. 21*s*.

A Lecture on Dysmenorrhœa. By R. A. GIBBONS, M.D., F.R.C.S.E., Physician to the Grosvenor Hospital for Women. 2*s*. net.

BY THE SAME AUTHOR.

A Lecture on Sterility: its Ætiology and Treatment. 2*s*. net.

Medical Jurisprudence Ophthalmology

Medical Jurisprudence: its Principles and Practice. By ALFRED S. TAYLOR, M.D., F.R.C.P., F.R.S. Sixth Edition, by FRED. J. SMITH, M.D., F.R.C.P., Physician to, and Lecturer on Forensic Medicine at, the London Hospital. 2 vols. 20 Engravings. 42*s.* net.

Lectures on Medical Jurisprudence and Toxicology. By FRED. J. SMITH, M.D., F.R.C.P., F.R.C.S.Eng., Physician to, and Lecturer on Forensic Medicine and Toxicology at, the London Hospital. Second Edition. 8*s.* 6*d.* net.

Medical Ophthalmoscopy: A Manual and Atlas. Fourth Edition. By SIR W. R. GOWERS, M.D., F.R.S., and MARCUS GUNN, M.B., F.R.C.S., Surgeon to the Royal London Ophthalmic Hospital. Autotype Plates and Woodcuts. 14*s.* net.

Manual of Ophthalmic Surgery and Medicine. By W. H. H. JESSOP, M.A., F.R.C.S., Senior Ophthalmic Surgeon to St. Bartholomew's Hospital. Second Edition. 8 Plates and 155 other Illustrations. 9*s.* 6*d.* net.

Refraction of the Eye: a Manual for Students. By GUSTAVUS HARTRIDGE, F.R.C.S., Consulting Surgeon to the Royal Westminster Ophthalmic Hospital. Fifteenth Edition. 107 Illustrations, also Test-types, etc. 5*s.* net.

BY THE SAME AUTHOR.

The Ophthalmoscope: a Manual for Students. Fifth Edition. 68 Illustrations and 4 Plates. 4*s.* net.

Diseases of the Eye: a Manual for Students and Practitioners. By J. HERBERT PARSONS, D.Sc., M.B., B.S., F.R.C.S., Assistant Ophthalmic Surgeon, University College Hospital; Assistant Surgeon, Royal London (Moorfields) Ophthalmic Hospital. 308 Illustrations and 15 Plates. 10*s.* 6*d.* net. *Second Edition ready early, in* 1912.

BY THE SAME AUTHOR.

Elementary Ophthalmic Optics, including Ophthalmoscopy and Retinoscopy. 66 Illustrations. 6*s.* 6*d.*

Sight Testing made Easy, including Chapter on Retinoscopy. By W. W. HARDWICKE, M.D., M.R.C.P., late Hon. Physician, Molesey and Hampton Court Cottage Hospital. Second Edition. 12 Engravings. 2*s.* 6*d.* net.

Royal London Ophthalmic Hospital Reports. By the Medical and Surgical Staff. Vol. XVIII, Part II. 5*s.* net.

Ophthalmological Society of the United Kingdom. Transactions. Vol. XXX. 12*s.* 6*d.* net. Also in Three Fasciculi at 4*s.* net each.

Otology ✐ Pædiatrics ✐ Dentistry

The Labyrinth of Animals, including Mammals, Birds, Reptiles, and Amphibians. By ALBERT A. GRAY, M.D.(Glas.), F.R.S.E., Surgeon for Diseases of the Ear to the Victoria Infirmary, Glasgow. Vol. I, with 31 Stereoscopic Plates 21*s*. net (including Stereoscope). Vol. II, with 45 Stereoscopic Plates, 25*s*. net.

Some Points in the Surgical Anatomy of the Temporal Bone from Birth to Adult Life. By ARTHUR H. CHEATLE, F.R.C.S., Aural Surgeon to King's College Hospital. 112 Illustrations. 5*s*. net.

Diseases of the Ear, including the Anatomy and Physiology of the Organ, together with the Treatment of the Affections of the Nose and Pharynx. By T. MARK HOVELL, Senior Aural Surgeon to the London Hospital. Second Edition. 128 Engravings. 21*s*.

The Diseases of Children. By SIR JAMES F. GOODHART, Bart., M.D., F.R.C.P., and G. F. STILL, M.D., F.R.C.P., Professor of the Diseases of Children, King's College. Ninth Edition. 34 Illustrations. 15*s*. net.

The Wasting Diseases of Infants and Children. By EUSTACE SMITH, M.D., F.R.C.P. Sixth Edition. 6*s*.

On the Natural and Artificial Methods of Feed- ing Infants and Young Children. By EDMUND CAUTLEY, M.D., Physician to the Belgrave Hospital for Children. Second Edition. 7*s*. 6*d*.

Your Child's Health: Medical Notes for Mothers and Teachers, School Nurses and Health Visitors. By JOHN GRIMSHAW, M.D., B.S.(Lond.). 2*s*. 6*d*. net. **Health Talks about Children.** 1*s*. net. **Eye-strain and Eyesight.** 1*s*. net.

Dental Anatomy, Human and Comparative: a Manual. By CHARLES S. TOMES, M.A., F.R.S. Sixth Edition. 286 Engravings. 12*s*. 6*d*. net.

BY THE SAME AUTHOR.

A System of Dental Surgery. By Sir JOHN TOMES, F.R.S. Revised by C. S. TOMES, M.A., F.R.S., and WALTER S. NOWELL, M.A.Oxon. Fifth Edition. 318 Engravings. 15*s*. net.

Practical Treatise on Mechanical Dentistry. By JOSEPH RICHARDSON, M.D., D.D.S. Seventh Edition, revised and edited by GEORGE W. WARREN, D.D.S. 690 Engravings. 22*s*.

An Atlas of Dental Extractions, with Notes on the Causes and Relief of Dental Pain. By C. EDWARD WALLIS, M.R.C.S., L.R.C.P., L.D.S., Assistant Dental Surgeon, King's College Hospital. With 11 Plates. 3*s*. 6*d*. net.

Decay in Teeth: an Investigation into its Cause and Prevention. By J. SIM WALLACE, M.D., D.Sc., L.D.S.R.C.S. Second Edition. 5*s*.

A Manual of Dental Metallurgy. By ERNEST A. SMITH, Assay Office, Sheffield. Third Edition. 38 Illustrations. 6*s*. 6*d*. net.

Dental Materia Medica, Pharmacology, and Therapeutics. By CHARLES W. GLASSINGTON, M.R.C.S., L.D.S.Edin.; Senior Dental Surgeon, Westminster Hospital. Second Edition. 6*s*. net.

Dermatology & Tropical Diseases

A Text-Book of Diseases of the Skin. By J. H. SEQUEIRA, M.D., F.R.C.P., F.R.C.S., Physician to the Skin Department and Lecturer on Dermatology, London Hospital. Illustrated with 44 Plates in Colours and 179 Text-figures. 25*s*. net.

A Manual of Diseases of the Skin, with an Analysis of 20,000 Consecutive Cases and a Formulary. By DUNCAN E. BULKLEY, M.D., New York. Fourth Edition. 6*s*. 6*d*.

Skin Diseases of Children. By GEO. H. FOX, M.D., Clinical Professor of Diseases of the Skin, College of Physicians and Surgeons, New York. 12 Plates and 60 Illustrations in the Text. 12*s*. 6*d*.

On Maternal Syphilis, including the Presence and Recognition of Syphilitic Pelvic Disease in Women. By JOHN A. SHAW-MACKENZIE, M.D. Coloured Plates. 10*s*. 6*d*.

The Diagnosis and Treatment of Syphilis. By TOM ROBINSON, M.D.St. And., Physician to the Western Skin Hospital. Second Edition. 3*s*. 6*d*. **The Diagnosis and Treatment of Eczema.** Second Edition. 3*s*. 6*d*.

A Handbook on Leprosy. By S. P. IMPEY, M.D., late Chief and Medical Superintendent, Robben Island Leper and Lunatic Asylums, Cape Colony. 38 Plates. 12*s*.

The Malarial Fevers, Hæmoglobinuric Fever and Blood Protozoa of Man. By CHARLES F. CRAIG, M.D., Captain U.S. Army. With 4 Coloured Plates and numerous Charts and Drawings. 20*s*. net.

Waring's Bazaar Medicines of India. See page 6.

Prout's Elementary Hygiene and Sanitation. See page 4.

The Malarial Fevers of British Malaya. By HAMILTON WRIGHT, M.D. (McGILL), Director of the Institute for Medical Research, Federated Malay States. Map and Charts. 3*s*. net. **The Etiology and Pathology of Beri-Beri.** With Map and Charts. 3*s*. net.

Studies from Institute for Medical Research, Federated Malay States. Vol. III. 10*s*. net.

Report on the Prevention of Malaria in Mauri- tius. By SIR RONALD ROSS, K.C.B., D.P.H., F.R.C.S., F.R.S., Professor of Tropical Medicine, University of Liverpool. With 25 Illustrations. 5*s*. net.

On the Causes and Continuance of Plague in Hong Kong. By W. J. SIMPSON, M.D., F.R.C.P. 10*s*. net. **Report on Plague in the Gold Coast in 1908.** Illustrated. 2*s*. net.

On the Outbreak of Yellow Fever in British Honduras in 1905. By Sir RUBERT BOYCE, M.B., F.R.S. 3*s*. 6*d*. net.

Chemistry & Physics

The Elements of Chemistry. By M. M. PATTISON MUIR, M.A., Fellow of Caius College, Cambridge. Illustrated. 10s. 6d. net.

The Analyst's Laboratory Companion: a Collection of Tables and Data for Chemists and Students. By A. E. JOHNSON, B.Sc., F.I.C. Third Edition. 6s. 6d. net.

Commercial Organic Analysis: a Treatise on the Properties, Modes of Assaying, Proximate Analytical Examination, etc., of Organic Chemicals and Products used in the Arts, Manufactures, Medicine, etc. By A. H. ALLEN, F.I.C. Fourth Edition, in 8 vols. Edited by W. A. DAVIS, B.Sc., A.C.G.I, HENRY LEFFMANN, M.A., M.D., and S. S. SADTLER, S.B. Vols. 1, 2, 3, 4, and 5 ready. 21s. net. each. [Prospectus on application.]

Volumetric Analysis; or, the Quantitative Esti- mation of Chemical Substances by Measure. By FRANCIS SUTTON, F.C.S., F.I.C. Tenth Edition. 121 Engravings. 21s. net.

A Manual of Chemistry, Theoretical and Prac- tical. By Sir WILLIAM A. TILDEN, D.Sc., F.R.S., Professor of Chemistry in the Royal College of Science, London. 2 Plates and 143 Woodcuts. 10s.

Valentin's Practical Chemistry. By Dr. W. R. HODGKINSON, F.R.S.E., Professor of Chemistry and Physics in the Ordnance College, Woolwich. Tenth Edition. 14 Plates and 83 Figures in the Text. 10s. net.

Qualitative Analysis and Practical Chemistry. By FRANK CLOWES, D.Sc.Lond., Emeritus Professor of Chemistry in the University Coll., Nottingham. Eighth Edition. 102 Engravings. 7s. 6d. net.

Quantitative Analysis. By FRANK CLOWES, D.Sc.Lond., and J. B. COLEMAN, A.R.C.Sci. Dub.; Professor of Chemistry, South-West London Polytechnic. Ninth Edition. 133 Engravings. 10s. 6d. net.

BY THE SAME AUTHORS.

Elementary Practical Chemistry.
Part I. Fifth Edition. General Chemistry. 75 Engravings. 2s. 6d. net.
Part II. Sixth Edition. Analytical Chemistry. 20 Engravings. 3s. 6d. net.

A Course of Practical Chemistry for the Use of Public Schools. By A. BERESFORD RYLEY, M.A.(Oxon.), Assistant Master, Malvern College. Illustrated. Interleaved. 4s. 6d. net.

Introduction to Chemical Analysis. By HUGH C. H. CANDY, B.A., B.Sc., F.I.C., Lecturer on Chemistry in the London Hospital Medical College, Analyst to the London Hospital. 3s. 6d. net.

Researches on the Affinities of the Elements and on the Causes of the Chemical Similarity or Dissimilarity of Elements and Compounds. By GEOFFREY MARTIN, B.Sc Lond. Illustrated. 16s. net.

A Handbook of Physics and Chemistry for the Conjoint Board. By H. E. CORBIN, B.Sc.Lond., and A. M. STEWART, B.Sc.Lond. Fourth Edition. 183 Illustrations. 7s. 6d. net.

A Treatise on Physics. By ANDREW GRAY, LL.D., F.R.S., Professor of Natural Philosophy in the University of Glasgow. Vol. I. Dynamics and Properties of Matter. 350 Illustrations. 15s.

N91 Fenwick, Edwin Hurry
F343 Value of radiography in
1908 urinary stone 39434

NAME	DATE DUE
Frank Hinman ret. Mar. 19, 1915.	APR 12 1915
Dr. Wilbur. ret. Sept. 19, 1915.	SEP 19 1915
Boardman ret. Jan. 19, 1917.	
U. C. Med. School	APR 21 2000
J. T. CHENG, Radiol. Dept.	DEC 19 1965
(no change)	

N91 Fenwick, Edwin Hurry
F343 Value of radiography in
1908 urinary stone 39434

NAME	DATE DUE
Frank Hinman ret. May 19, 1915.	APR 12 1915
Dr. Wilbur, ret. Sept. 19, 1915.	SEP 28 1915
Boardman ret. Jan. 19, 1917.	
U.C. Med. School	APR 11 '2
J. T. CHENG, Biochem. Dept.	DEC 19 1965
(no change)	